
Prostate Cancer Diagnosis: Biopsy Approaches

Paul Gravestock¹ • Matthew Shaw¹ • Rajan Veeratterapillay¹ • Rakesh Heer^{1,2}

¹Department of Urology, Freeman Hospital, Newcastle Upon Tyne, Tyne and Wear, UK;

²Translational and Clinical Research Institute, NU Cancer, Newcastle upon Tyne, Tyne and Wear, UK

Author for correspondence: Rakesh Heer, Translational and Clinical Research Institute, NU Cancer, Newcastle upon Tyne, Tyne and Wear, UK.

Email: rakesh.heer@newcastle.ac.uk

Cite this chapter as: Gravestock P, Shaw M, Veeratterapillay R, Heer R. Prostate Cancer Diagnosis: Biopsy Approaches. In: Barber N and Ali A, editors. *Urologic Cancers*. Brisbane (AU): Exon Publications. ISBN: 978-0-6453320-5-6. Online first 13 Jul 2022.

Doi: <https://doi.org/10.36255/exon-publications-urologic-cancers-prostate-cancer-biopsy>

Abstract: Prostate cancer is a common and increasing malignancy in men. Tissue is generally obtained using prostate biopsy for diagnosis and risk stratification. There are many prostate biopsy techniques. Historically, the transrectal approach has been the most adopted. In many centers, however, there has been a shift towards transperineal prostate biopsies, increasingly performed under local anesthetic. The transperineal approach has proven advantages, including better sampling of the anterior area of the prostate and lower infection rates. Biopsies are typically performed using a combination of a systematic and targeted approach. Targeting of lesions identified by magnetic resonance imaging can be performed cognitively, assisted by a fused imaging approach with the transrectal ultrasound, or directly within the magnetic resonance imaging scanner. There are several novel developments in the field, which include robotic techniques to guide biopsy needles based on fusion images or directly targeting lesions robotically during in-bore magnetic resonance imaging.

In: Barber N, Ali A (Editors). *Urologic Cancers*. Exon Publications, Brisbane, Australia.

ISBN: 978-0-6453320-5-6. Doi: <https://doi.org/10.36255/exon-publications-urologic-cancers>

Copyright: The Authors.

License: This open access article is licenced under Creative Commons Attribution-NonCommercial 4.0 International (CC BY-NC 4.0) <https://creativecommons.org/licenses/by-nc/4.0/>

Keywords: image-guided prostate biopsy; magnetic resonance imaging for prostate biopsy; prostate biopsy approaches; transperineal prostate biopsy; transrectal prostate biopsy

INTRODUCTION

Prostate cancer is common. In 2020, it was the second most frequent malignancy in men worldwide. The highest incidence is found in Northern and Western Europe, the Caribbean, and Australasia; the lowest is in Asia and Northern Africa (1). Non modifiable risk factors include advancing age, ethnicity, and family history with a link to the BRCA gene mutation (1, 2). Numerous modifiable risk factors have also been identified and include smoking, levels of physical activity, metabolic syndrome, and sexual activity/ejaculatory frequency (1–5). Various dietary factors have been attributed to prostate cancer development and include well-done meat, sugar-sweetened beverages, dairy products, and processed foods (1, 2, 6–8).

Prostate cancer is often initially detected opportunistically by blood tests examining levels of prostate specific antigen (PSA) or by digital rectal examination (DRE). The latter examination relies on user experience and has been found to have a low sensitivity of around 50% in a primary care setting (9). PSA is a protease secreted by the prostate gland that has been utilized as a biomarker for prostate cancer since the late 1980s (10). It is not only useful in diagnosis but also for risk stratification and, following treatment, as a marker of recurrence (11). Widespread screening for prostate cancer using PSA, however, is a contentious issue. Evidence suggests that PSA screening can identify additional cancers; however the majority are low grade with no improvement seen in overall survival as a result (12). As such, international guidance focuses on individualized risk and shared decision making with risk-benefit discussion so that patients are informed of the potential for false positives and over-investigation/treatment before undertaking a PSA test (11, 13, 14).

Where there is suspicion of localized prostate cancer, such as abnormal DRE or raised PSA, further investigation is usually with multiparametric magnetic resonance imaging (mpMRI) of the prostate (11, 15, 16). mpMRI should be reported using the Likert or Prostate Imaging-Reporting and Data System (PI-RADS) scoring systems which standardize interpretation. Both systems score the investigation on a scale of 1 to 5 whereby 1 suggests that clinically significant disease is highly unlikely to be present and 5 suggests it is highly likely to be present (17, 18).

Biopsies are usually performed for abnormal DRE or mpMRI result suggestive of clinically significant disease, though the decision for biopsy should always be made in clinical context and in discussion with the patient. The use of prostate cancer risk calculators can assist decision making and are advocated by guidelines (11, 15). Prostate biopsies aim to confirm the diagnosis and assess the histological architecture using the Gleason grade, which is used to create a Gleason score, or more recently ISUP grade (19, 20). The Gleason score or ISUP grade is then used alongside mpMRI staging and PSA to stratify locally advanced prostate cancer risk. Risk groups vary depending on the guideline typically utilizing a 3-tier

system of low, intermediate, and high risk (11, 21). In the United Kingdom (UK) however the National Institute for Health and Care Excellence (NICE) have recently adopted the Cambridge Prognostic Criteria (CPG) which is a 5-tier system (22). There is evidence that suggests that the CPG system may allow for more accurate prognostication and therefore more specific and appropriate treatment (22, 23). Once risk-stratified, patients can then be counselled on treatment options appropriate for their prostate cancer, with active surveillance usually offered to the lower risk groups and radical treatment for those at higher risk (11, 21, 22). This underlines the importance of accurate histological information obtained from biopsy.

PROSTATE BIOPSY PRINCIPLES

Prostate biopsy was originally performed by targeting abnormalities felt on DRE with a biopsy needle (24). Whilst biopsy is still commonly undertaken by a transrectal (TR) approach, the methodology and improvements in targeting abnormalities have improved considerably. Furthermore, there has been a shift toward a transperineal approach. The practicality and merits of different approaches and techniques are discussed herein.

Prostate anatomy

Anatomically, the prostate is divided into glandular zones—comprising of peripheral, central and transitional zones—and non-glandular anterior fibromuscular zone, all of which are contained within the prostatic capsule (Figure 1) (25). Additionally, the peri-urethral zone is a thin layer of tissue around the urethra consisting of small ducts which can give rise to the median lobe in benign prostate hypertrophy (BPH) (26).

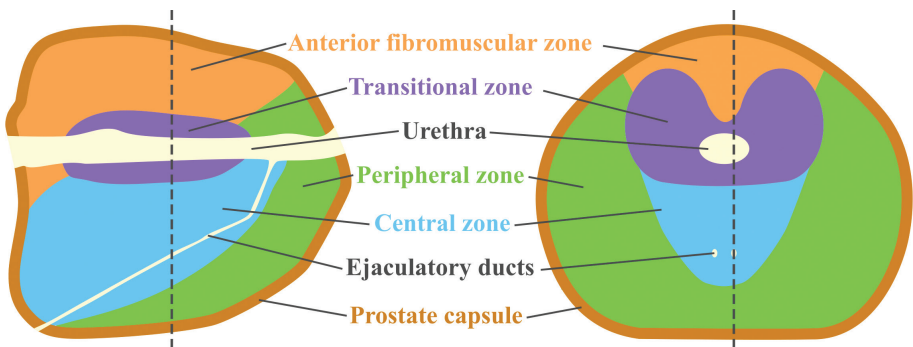


Figure 1. Zonal anatomy of the prostate. Parasagittal (left) and transverse (right) sections of the prostate, where dotted lines represent their intersection. The diagram illustrates the zonal anatomy, anterior fibromuscular zone in orange, peripheral zone in green, transitional zone in purple and central zone in blue.

Transrectal ultrasound

As a diagnostic modality, transrectal ultrasound (TRUS) has been found to have a low accuracy for detecting prostate cancer (27, 28). As a result, TRUS is primarily used to visualize and guide biopsy needles during the procedure (29).

Procedural analgesia

Prostate biopsy is recognized to be an uncomfortable procedure. Pain caused by TR biopsy is multifactorial, initially arising from the insertion of the probe, followed by piercing of the rectal mucosa and prostatic capsule (30). Insertion of the probe stimulates rectal stretch receptors, and some evidence suggests that those with a low anorectal compliance find biopsies more uncomfortable (31). Rectal mucosa is considered to be insensate proximal to the dentate line, however, apical biopsies may traverse this boundary due to the acute angle required and are considered among the most painful location to biopsy by the TR approach (30, 32). Prostatic innervation is predominately from within the capsule, pain appears to increase with the number cores taken with a cumulative effect, increasing after each consecutive biopsy (30, 33, 34). It has also been observed that younger patients report a higher rate of discomfort (31, 35, 36).

Analgesia is therefore an important component of the procedure, as whilst many men are able to tolerate the procedure without, in those who find it particularly uncomfortable it can limit the procedure and lead to refusal of re-biopsies, if required (32, 37, 38). Periprostatic nerve blockage (PNB) has been found to be an effective method of reducing pain during the procedure (39, 40). The extra injections required for a PNB do not appear to confer additional risk, including that of infection, although operators need to be mindful of local anesthetic (LA) toxicity which can occur if it is injected directly into the prostatic venous plexus (39–42). PNB is performed using a spinal needle under ultrasound guidance, 1% lidocaine is typically the agent of choice and between 5–10 ml of this is utilized, with evidence suggesting 10 ml to be an optimal dose (43). There are a multitude of approaches, the most common is the basal block whereby LA is infiltrated in the space between the seminal vesicle and prostate on either side, this area is identifiable as a hyperechoic pyramid on ultrasound termed “Mount Everest” sign (44, 45). Apical blocks have also been described alone or in combination with the basal technique, though there is conflicting evidence with some studies concluding equivocal efficacy and others suggesting apical approach may be superior (43, 46–50). Discomfort caused by probe insertion is not ameliorated by PNB and is part of the procedure that some men find the most uncomfortable (49). Additional topical anesthetic, usually in the form of intrarectal lidocaine gel, is therefore commonly used in combination with PNB and can safely reduce pain associated with probe insertion (39, 40). A less commonly used alternative to intrarectal lidocaine is topical glyceryl trinitrate (GTN) which has also been shown to be effective (51, 52).

Transperineal (TP) biopsies were initially performed under a general anesthetic (GA) but increasingly are undertaken as a LA procedure. In these cases, LA is infiltrated into the perineal skin prior to a PNB performed as described above but via the perineum (53, 54).

Equipment

An endorectal ultrasound transducer with a frequency in the range of 6–12 MHz is commonly used. Ideally, transducers should be biplane, allowing visualization of transverse and longitudinal sections simultaneously (55). When utilizing the probe for TR biopsies, two main types exist: (i) end-firing with a biopsy needle which runs parallel to the probe with a curved transducer at the tip allowing for biopsies to be taken in the sagittal or transverse plane (56, 57); and (ii) side-firing probes wherein the biopsy needle traverses the probe and a longitudinal transducer allows for biopsies to be visualized in the sagittal plane (56, 57). Initially retrospective studies suggested better prostate cancer detection with the end-firing probe because of its ability to sample apical and lateral regions of the prostate; however, subsequent randomized control trials have shown no difference between the techniques (56, 58–61).

Biopsies were originally performed using hand-driven needles but have universally shifted to the use of a spring-loaded biopsy needle gun due to gun-driven biopsies providing better tissue yields (62, 63). There are multiple biopsy guns available on the market, the majority utilize 18-gauge needles that are between 20–25 cm long. The mechanism consists of a double trocar where an inner trocar is fired into tissue, followed by an outer trocar around this to cut the tissue core; the outer trocar then retracts and the tissue can be retrieved via the tissue tray, a windowed aspect of the inner trocar (64).

Depending on the ultrasound machine, markers are typically superimposed onto the image at 5 mm intervals to allow estimate of where the gun will fire, the needle typically fires 25 mm into tissue with the windowed aspect present in the middle 15 mm. It was initially reported that tissue obtained in the first 5mm would not be contained within the biopsy and that position should be adjusted as such; however, this has subsequently been shown not to be the case (64, 65).

Biopsy core length improves quality of tissue and sensitivity for diagnosis with suggestion that 12 mm is the minimum length required, whereas needle diameter does not appear to improve prostate cancer detection rates (66–71). Most biopsy guns are designed to obtain standard core lengths of 20 mm, some devices have been designed to take longer cores, though longer needles have an increased risk of deflection and therefore potentially lower sampling accuracy (72, 73).

Procedure

Transrectal biopsies are typically performed in the left lateral decubitus position with knees and hips flexed to approximately 90 degrees. Transperineal biopsies are most commonly performed in the lithotomy position, though the left lateral decubitus position has been described (74). A DRE is carried out prior to assess the prostate and correlate with ultrasound. Palpable abnormalities should be considered for targeting at biopsy. The probe is introduced with lubricant and analgesia administered as discussed. Prostate size, specifically volume, can be estimated using the ellipsoid volume formula which can be used to calculate the PSA density, or in patients with benign prostatic hypertrophy, can be used for treatment planning. Biopsies can then be taken in either a systematic or targeted approach. The transrectal and transperineal biopsy techniques are shown in Figure 2.

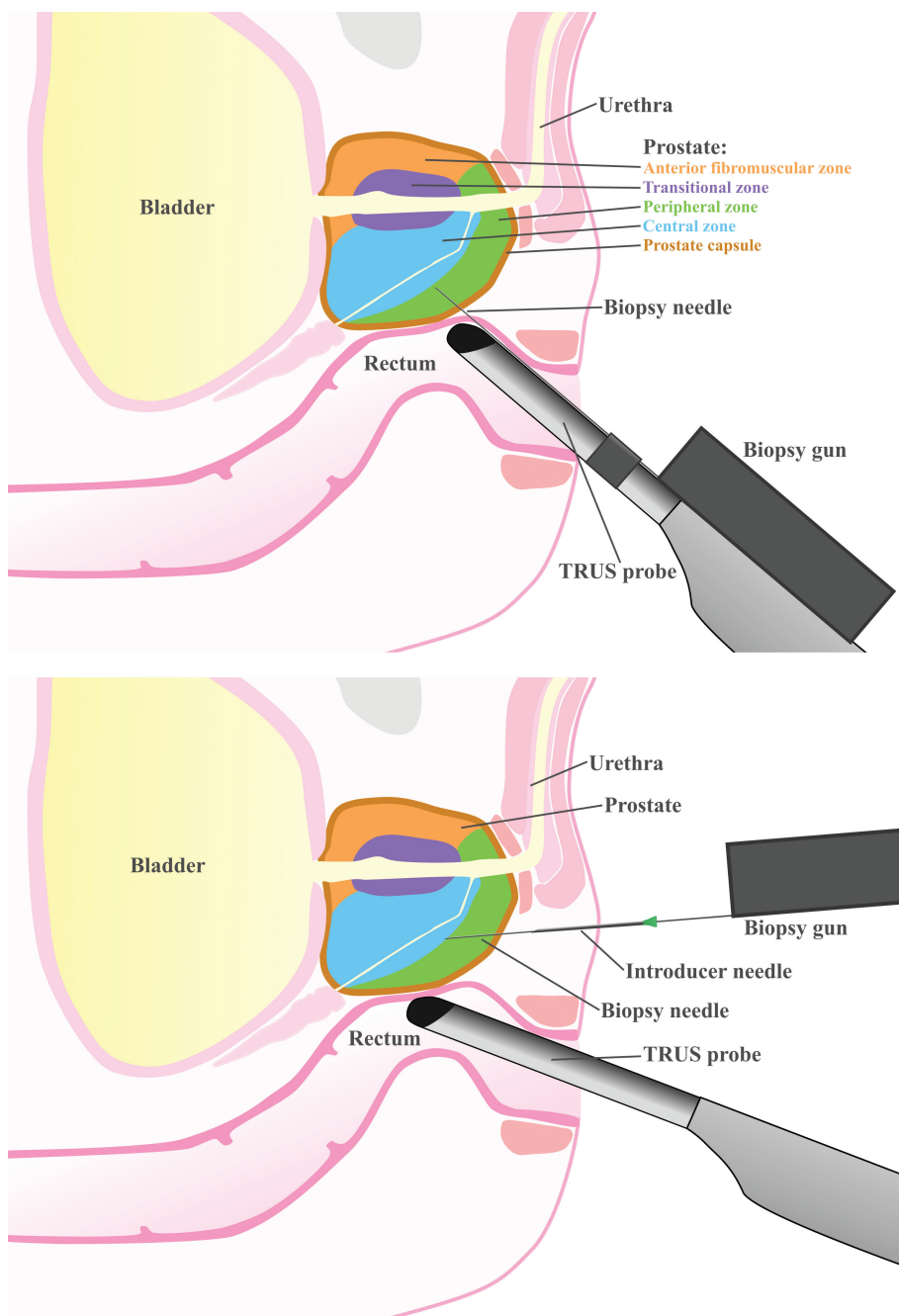


Figure 2. Parasagittal view of a prostate biopsy. Top, Transrectal approach using an end-firing probe. Bottom, Transperineal approach using the double freehand technique.

One aspect this illustrates is the difficulty of sampling the anterior prostate by the transrectal approach, an area which is more readily accessed by TP biopsy (75, 76).

SYSTEMATIC BIOPSIES

There are several systematic biopsy protocols. Initially, when transrectal prostate biopsy was developed, it was using a sextant pattern, with 3 cores taken from each side of the prostate, and was found to be superior to targeting lesions identified using TRUS (29). However, the sextant protocol has been found to have a high false negative rate, particularly missing apical and lateral lesions (77–79).

Transrectal extended systematic biopsy

Several alternative biopsy protocols have been examined with studies suggesting sensitivity can be increased by increasing the number of biopsy cores taken (29, 77–80). Further evidence, including a large systematic review, has suggested that 10–12 cores seem to be an optimal number, in what is termed an extended biopsy, and which has now become the standard of care (11, 81–83). The extended biopsy utilizes the traditional sextant biopsy with additional cores taken from the more lateral aspects of the prostate which has been shown to increase diagnostic yield (77, 84). The number of cores taken should be adjusted based on the size of the prostate with smaller prostates requiring fewer cores (84). An example of core sampling locations is shown in Figure 3.

Transrectal saturation biopsy

Transrectal saturation biopsy was developed in response to patients with a high clinical suspicion of prostate cancer who had undergone multiple negative biopsies;




Figure 3. Prostate biopsy schemes. Examples of sextant (left) and extended ten core (right) prostatic biopsy schemes as seen in the coronal plane, from the perspective of a TRUS biopsy.

it involves taking a much higher number of cores, usually between 20–30 (85). In the original 2001 paper, a detection rate of 34% was found amongst men who on average had undergone two previous negative sextant biopsies (85). Following its development, standard practice has now changed with patients undergoing extended biopsy protocols plus targeted biopsies in most cases. However, the role for saturation biopsy remains for those patients with negative biopsy and high clinical suspicion; this is typically in the context of persistently high PSA or abnormal mpMRI.

Transperineal template mapping biopsy

Transperineal biopsies initially were developed using the grid and stepper technique to perform a systematic saturation biopsy of the prostate under general anesthetic. This technique utilizes the brachytherapy needle guide developed for insertion of radioactive seeds and consists of a grid punctuated with holes to pass a needle spaced 5mm apart. If sampling the whole gland, this can result in 50–70 cores being taken. This method is highly sensitive, missing only 5% of small prostatic lesions compared with 30–40% missed at TRUS biopsy (86).

Transperineal biopsy schemes

To reduce the number of cores taken, various biopsy schemes utilizing the grid and stepper exist. The Ginsberg scheme was defined in 2013 to standardize this (87). The number of cores sampled is dependent on prostatic size but broadly splits the prostate into three sectors on each side, anterior, mid, and posterior, with four cores taken from each, and additional cores from a basal sector used in large prostates totaling 24 or 32 cores respectively (87). The Ginsberg scheme has been shown to yield high rates of cancer detection and is illustrated in Figure 4 (88). Whilst some studies report grid biopsies performed under local anesthetic, due to

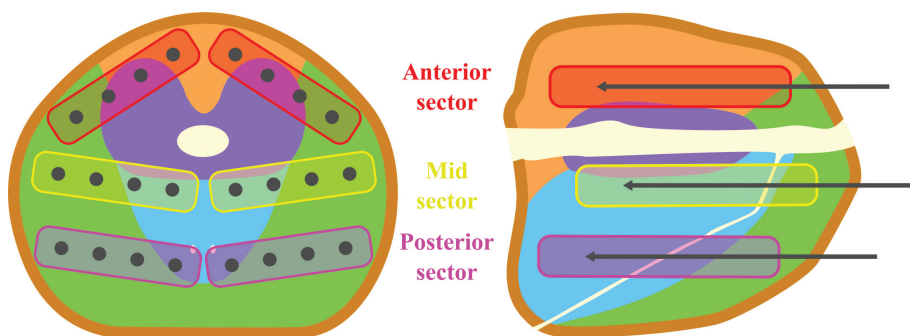


Figure 4. Schematic demonstrating the Ginsburg protocol for a small prostate (<30 cc) in parasagittal and axial views. Sampling locations are shown across three sectors with four cores taken from each bilaterally, totalling 24 cores. Prostatic zones are as previously labelled in Figure 1: anterior fibromuscular zone in orange, peripheral zone in green, transitional zone in purple and central zone in blue. Adapted from the description of the Ginsburg Protocol by Kuru et al. (87).

the large number of needle punctures via the perineum and a wide spread of local anesthetic that is required, this technique is generally performed under general or regional anesthesia (89, 90). To better facilitate transperineal biopsies under a local anesthetic, alternative techniques have been described.

Transperineal freehand technique

These include the freehand technique whereby a single puncture with an introducer needle is made on either side of the perineum and the biopsy needle passed through, thereby removing the need for multiple skin punctures and allows for local anesthetic to be localized to the limited points of puncture. Typically, local anesthetic is infiltrated in the skin with a 23- or 25-gauge needle, following which a finer spinal needle can be used to infiltrate the subcutaneous tissue, muscular diaphragm and space around the prostate apex as described earlier (91). The number of cores taken using this technique vary with some authors obtaining a smaller number of cores similar to a transrectal biopsy and others following the Ginsberg protocol (53, 91–93). Similar rates of cancer detection have been seen when comparing 10 core transperineal and transrectal biopsy and a systematic review has confirmed similar diagnosis rates between the transrectal and transperineal approach (90, 94). Tolerability of this technique appears to be good with one large series of patients reporting visual analogue pain scores (VAS) of up to 3.1/10 with the most painful aspect often reported as the infiltration of local anesthetic (53). Other series report similar results with average VAS scores between 1–5 (90, 93, 95–97). With one reporting only one of 181 patients abandoning the procedure due to discomfort (96). Advantages of the freehand technique include the reduction of urinary retention rates when compared to the grid technique. In one study, this was 10% for those undergoing grid biopsies and 1% for free-hand, despite a similar number of cores being taken (31 vs 28) (91).

TARGETED PROSTATE BIOPSIES

Whilst systematic biopsies are useful at sampling the prostate, targeting abnormal lesions directly, previously practiced in conjunction with abnormal DRE or TRUS images, has become more relevant with the increasing use of mpMRI.

Ultrasound targeted

Hypoechoic lesions on TRUS can often represent prostate cancer and evidence suggests that hypoechoic lesions seen during systematic biopsy are predictors for clinically significant prostate cancer (98–101). However, whether routinely targeting these lesions increases diagnostic yield is less conclusive with conflicting results. One prospective study found no higher detection rate in hypoechoic lesions compared with isoechoic areas whereas another found that 9% of cancers were only present in the cores from hypoechoic lesions and would have been missed by systematic biopsy alone (102, 103). Further studies have reported more modest results with around 3–4% of additional cancers detected solely on cores targeting hypoechoic lesions (104, 105).

MRI targeted

For those patients who have a mpMRI suspicious for cancer, there is strong evidence that there is improved cancer detection if abnormal lesions identified on mpMRI are targeted at biopsy, and reduced diagnoses of clinically insignificant cancers if systematic biopsies are omitted (106–111). Though mpMRI targeted biopsies have been shown to be non-inferior to systematic biopsies, individual studies have shown that mpMRI targeted biopsies alone miss a small proportion, 4–16%, of clinically significant cancers that would be picked up with additional systematic biopsies (112–118). Current guidance is to offer combined systematic and targeted biopsies (11). There is no standard number of cores recommended from each target but a systematic review analyzing diagnostic yield per number of cores taken from mpMRI-targeted biopsies showed incremental gains with each additional core taken, but this benefit became minor after three cores (119). It is generally accepted that in patients who have a negative mpMRI but retain a strong clinical suspicion for prostate cancer, a systematic biopsy should be undertaken (11). This is because whilst mpMRI has a sensitivity for clinically significant prostate cancer of greater than 90%, a small proportion of lesions are not visible; furthermore, mpMRI has been shown to have a lower negative predictive value for those with high PSA (120, 121). Note that a threshold for clinically significant prostate cancer is not clearly defined with a variety of thresholds throughout the literature, though the definition most often used within studies tends to be a Gleason score ≥ 7 (22).

Cognitive targeting

mpMRI-targeted biopsies can be performed in several ways, the most straightforward is cognitive targeting (also known as cognitive fusion or visual estimation) whereby the operator uses the MRI images/report to help direct biopsies at a suspicious area. In this method, the biopsy is conducted by targeting areas on the TRUS images that would correspond to the area on the MRI and can be performed using either the transrectal or transperineal approach. Cognitive targeting using the transperineal approach can be done using a ‘double freehand’ technique whereby the introducer needle placed in the perineum is separate from the TRUS probe. This is practically more difficult as it requires the operator to manually align the TRUS probe with the needle to keep it in view. To make this technique more user friendly, a selection of devices to assist the process have been introduced. These devices incorporate a guide attached to the probe to keep the needle in line, and hence in view, to enable easier targeting.

Transrectal ultrasound-mpMRI (TRUS-MR) fusion biopsies

TRUS-MR fusion biopsies involve specialized software to overlay areas of interest seen on mpMRI onto TRUS images in real-time so that they can be readily targeted. Two main methods for registering mpMRI images onto TRUS exist; rigid registration whereby images are simply overlaid, or elastic registration which uses software to manipulate the overlaid MRI images to take into account deformation of prostatic anatomy caused by the manipulation of the rectal ultrasound probe.

Whilst some evidence suggests elastic registration is more accurate, the majority of clinical studies show no difference between the two modalities, with operator experience playing a key role in accuracy regardless of technique (122–124). Certainly, inter-operator variability and expertise is a factor, particularly for cognitive and fusion biopsy where a learning curve with higher detection rates of clinically significant prostate cancer associated with experience has been demonstrated (125–127). TRUS-MR fusion biopsies can be undertaken via the transrectal or transperineal approach though evidence suggests that the transperineal approach is better at detecting clinically significant cancers and anterior tumors with a lower rate of complications compared with transrectal (76, 128, 129).

In-bore magnetic resonance image-guided biopsies

In-bore MRI-guided biopsy, whereby MRI is used to guide the biopsy needle directly, avoids some of these difficulties (130). For transrectal in-bore MRI-guided biopsies, patients undergo a diagnostic prostate mpMRI and then return for a guided biopsy. This is usually performed prone using a needle guide which is adjusted and re-imaged until correctly positioned, at which point the biopsy needle is inserted, re-imaged and then biopsy taken (130). MRI compatibility is a key consideration, meaning devices need to be free of ferromagnetic/electronic materials that could interfere with image capture. Whilst the majority of systems use a transrectal approach, transperineal and transluteal techniques have been described (131, 132).

Evidence to support targeting methodology

The three MRI targeting techniques described above were compared in the FUTURE trial in men with previous negative systematic biopsy and PIRADS 3 or greater lesion on mpMRI, and no difference in detection rates was found between methods, though it was underpowered (133). Some evidence suggests improved detection of clinically significant prostate cancer and reduced detection of insignificant prostate cancer utilizing in-bore MRI compared with TRUS-MR Fusion (134). However, systematic reviews have shown none of the three above methods to be superior, though one did show a trend in favor of MRI-ultrasound fusion over cognitive targeting, at present there remains no clear consensus (135–137). Of note, there appears to be no additional complications seen in utilizing the fusion or in bore approach (138, 139). From a cost and logistics perspective performing in-bore MRI targeted biopsies is clearly a more costly and resource intensive procedure, requiring an MRI scanner, expertise, and compatible equipment. Cost effective analyses have shown cost of in-bore MRI biopsy is similar to general anesthesia transperineal biopsy but more than double that of a local anesthetic transrectal biopsy (140).

Robotic biopsies: TRUS-MR fusion-guided robotic biopsy

Robotic biopsy methods have been developed using TRUS-MR fusion. Various designs exist, though the general principle is that lesions identified on mpMRI and fused with TRUS images are targeted with the robotic arm which defines

penetration angle and depth by positioning a needle guide with stop bar (141–143). The insertion and firing of the needle gun are then performed by the surgeon at the predefined position and depth (142, 143). Though robotic fusion biopsy has been described by both a transrectal and transperineal approach, the majority utilize the latter. One advantage of this is that the system maps out the intended biopsies and correlates an appropriate pivot point to site the trocar needle thereby minimizing the need for repeated skin puncture (142, 143). Whilst the system can accurately target MRI lesions using fusion technology it can also be used to take systematic biopsies with initial studies still showing benefit of taking both targeted and systematic biopsies by this approach (142–145). Though the majority of these early studies utilize general anesthesia, there have been reports of its initial use under local anesthesia with sedation (146). To date, there is limited evidence for fusion robotic biopsy, though one retrospective study reported higher rates of detection for clinically significant cancers and lower complications with transperineal robotic biopsy compared with transperineal cognitive biopsies (147). Robotic guidance likely represents a method to reduce learning curve and standardize biopsies (147).

Robotic biopsies: MRI-guided robotic biopsy

Transrectal in-bore MRI robotic biopsies are performed similarly to standard in-bore MRI biopsy with patients in a prone position within the scanner. A rectal needle guide is inserted and attached to the robotic manipulator which sits between the patients' legs (148–151). The MRI is performed, and area of interest identified, following which the robotic transrectal needle guide is positioned using specialized software with the ability to fine tune the position of the needle path in line with the area to be biopsied (148–151). The robotic arm is MRI compatible by virtue of pneumatic stepper motors powered by compressed air from outside the MRI room (148–151). Once the needle guide is accurately positioned, the patient is removed from the bore of the machine and an MRI compatible transrectal biopsy gun is used within the guide to take a biopsy from the predetermined location (148–151). The advantage of this over the non-robotic method is the speed and ease of needle positioning which otherwise has to be performed manually with the patient removed from the scanner each time. Though there is limited evidence available on this technique at present, early reports suggest a high rate of success and cancer detection (148–151).

PROCEDURAL COMPLICATIONS

Despite being similar procedures, the complication profile of transrectal and transperineal biopsies varies, in particular with respect to the risk of infectious complications.

Infection in transrectal biopsies

For the transrectal approach, infection is a greater consideration due to the passage of the needle through rectal mucosa. Rates of post biopsy sepsis/severe infection

resulting in hospitalization have been reported in around 3% of patients, though up to 10% in one Norwegian series (152–157). Those most at risk of infectious complications include those with pre-biopsy bacteriuria, urethral catheterization, and prior urogenital infection (158). Multiple comorbidities, particularly diabetes mellitus, have been found to be associated with an increased risk of hospitalization (158). Of note, neither increased number of biopsy cores nor the use of a periprostatic nerve block appear to have any bearing on the rate of infectious complications (41).

Antibiotic prophylaxis in transrectal biopsy

A Cochrane review in 2011 concluded that antibiotic prophylaxis is effective at reducing infectious complications in TR biopsies (159). Subsequent evidence has confirmed that antibiotic prophylaxis is more effective if a minimum of 1 day duration is given and commenced at least 24 hours prior to biopsy (160, 161). A cause for concern is the observation of increased fluoroquinolone resistance in some centers, with a baseline prevalence estimated in a meta-analysis from 2012 of around 17% (152, 162, 163). Fluoroquinolone resistance has been found at higher rates in men who have undergone previous fluoroquinolone prophylaxis, those who have undertaken international travel, particularly to areas with increased resistance and those who have had recent hospital admission (158, 162). It has also been observed at higher rates in physicians and relatives of hospital employees (158, 162). Men with fluoroquinolone resistance have been shown to be at higher risk of infectious complications (162, 164). The significance of this appears to be an increase in infectious complications and resultant hospital admissions reported across multiple centers, with one large population study in Canada showing a rise in infection related admissions from 1% to 4% in 10 years (152, 163, 165, 166).

One approach used to combat this has been routine pre-biopsy swabs to determine if a patient has fluoroquinolone resistance, with prophylaxis tailored accordingly. Evidence has shown that this targeted prophylaxis approach reduces overall infectious complications, though rates of sepsis in some studies were found to be unchanged (161, 167, 168). Augmented prophylaxis is another approach, whereby multiple antibiotic agents are used in combination. This has been shown to reduce infectious complications compared to single agent prophylaxis with the majority of studies included within the metanalysis using fluoroquinolone as one of the agents, often in conjunction with an aminoglycoside (161). Recently, there has been concern with regards to increasing recognized adverse effects of fluoroquinolone antibiotics and their use in perioperative prophylaxis has been restricted in some regions (169, 170). As a result, there has been an increased emphasis on alternative antibiotics for prophylaxis. Fosfomycin has been found to be an effective prophylaxis with low rates of resistance and less infectious complications than fluoroquinolones (161, 171–173). Aminoglycoside, piperacillin/tazobactam, and cephalosporin prophylaxis has also found to be comparable to fluoroquinolones (159, 161, 174). Whereas co-amoxiclav has been shown to be less effective (175, 176). Single doses of pre-biopsy carbapenem antibiotics have also been used with good effect and some evidence suggests its use may not select for carbapenem resistant organism (177–180).

Non-antibiotic measures in transrectal biopsy

Non-antibiotic measures to reduce infectious complications include pre-biopsy rectal enema or rectal preparation with povidone-iodine. Pre-biopsy rectal enema appears to have no impact on rates of infectious complications/hospitalization (41, 159). Rectal preparation with povidone-iodine however has been shown to reduce both infectious complications and hospitalization (41). International guidance generally recommends using targeted or augmented prophylaxis alongside povidone-iodine rectal preparation (11, 181). EAU guidance however also strongly suggests considering the transperineal approach to reduce infectious complications (11).

Antibiotic prophylaxis in transperineal biopsy

In comparison to the transrectal approach, the risk of infectious complications in transperineal biopsy appears to be much lower with multiple studies reporting low rates of infectious complications with an incidence of sepsis ranging from 0–0.11% (53, 96, 97, 182–185). Whether antibiotic prophylaxis is required is an ongoing debate with its omission in some studies maintaining a low rate of infectious complications (1.9–3.6%) and no episodes of sepsis (90, 186, 187). A systematic review on the matter reported no significant difference in infectious complications for patients given antibiotic prophylaxis than those not with a pooled rate of infectious complications in the non-antibiotic prophylaxis group of 0.31% (185). Risk factors that have been identified for infectious complications in transperineal biopsy include diabetes mellitus and history of urinary retention (186). Interestingly, one study showed that asymptomatic patients with positive urine cultures pre-biopsy did not have an increased rate of urinary tract infection (188).

Urinary retention

Urinary retention is a risk of both transrectal and transperineal biopsies though transrectal biopsy appears to have a lower risk of retention than transperineal with one large UK population study reporting rates of readmission for retention at 1.9% vs 1% for transperineal and transrectal respectively (189). The figure of 1% for urinary retention post transrectal biopsy is supported by other literature reporting transrectal complication rates (182). There is a wide range of urinary retention rates post transperineal biopsy reported in the literature, between 0.05–10% with the lowest rates reported in local anesthetic freehand biopsies compared with higher rates in grid biopsies (87, 89, 90, 92, 181, 182, 185, 188).

Bleeding

Hematuria and hematospermia are common complications of transrectal and transperineal biopsies with rectal bleeding and perineal hematoma unique complications to transrectal and transperineal biopsies respectively (89, 184). Minor hematuria is common in both cohorts but significant bleeding requiring hospital admission is rare with similar rates reported for both approaches of around 1% (96, 183, 187, 189).

Concurrent use of antiplatelet and anticoagulant therapy

Concurrent use of aspirin during transrectal biopsies has been examined and systematic reviews have concluded that whilst it may increase or prolong minor bleeding, it is safe to continue, with an increase in risk of self-limiting rectal bleeding (190–192). The evidence on warfarin use during transrectal biopsies is limited by cohort size but several smaller studies report no increase in bleeding complications as a result of warfarinization (193–195). This suggests it may not be necessary to discontinue warfarin prior to biopsy, though a survey of urologists in 2010 found that 85% would do so routinely (196). Very little evidence exists to guide the use of novel oral anticoagulants (NOACs) such as apixaban and rivaroxaban, agents that are increasingly being utilized and as such further studies are required (197). Limited evidence exists for transperineal biopsy but in one study, in patients receiving antiplatelet or anticoagulant therapy, an increase in minor bleeding was noted but no severe bleeding events observed, though of note only a minority of patients were taking NOACs (198).

Erectile dysfunction

Erectile dysfunction is a common complication of both transrectal and transperineal biopsy. Systematic reviews report that prostate biopsy results in a decrease in erectile function at 1 month post biopsy which resolves spontaneously by 3–6 months, though the effect may persist slightly longer when biopsies are undertaken by transrectal as compared with transperineal approach (199, 200).

Needle tract seeding

Post biopsy seeding of cancer to the needle tract used during biopsy is incredibly rare. A review of the literature in 2015 identified 40 cases of this, 9 of these were taken via the transrectal approach and 31 via a transperineal approach. Seeding was generally seen in high grade disease. Of note, all of the transperineal biopsies were taken prior to 2000 generally using larger bore needles and although no correlation was observed by the authors in terms of needle devices, or diameter, it is fair to say that the approach used today is quite different (201).

Mortality

Death following prostate biopsy is rare, with rates up to 0.1% reported for both transrectal and transperineal biopsies. Additionally, studies have found that 120-day mortality rates in men undergoing prostate biopsies is no higher than in the control arm of men who did not undergo biopsy (202, 203).

CONCLUSION

Prostate biopsy is a key procedure in the diagnosis and risk stratification of prostate cancer. The transperineal approach is becoming more widely adopted

and increasingly under local anesthetic. Further developments in the field include an increase in targeting accuracy by the addition of robotic devices, however, there is a lack of evidence demonstrating the benefit of these at present.

Conflict of Interest: The authors declare no potential conflict of interest with respect to research, authorship and/or publication of this chapter

Copyright and Permission Statement: The authors confirm that the materials included in this chapter do not violate copyright laws. Where relevant, appropriate permissions have been obtained from the original copyright holder(s), and all original sources have been appropriately acknowledged or referenced.

REFERENCES

1. Gandaglia G, Leni R, Bray F, Fleshner N, Freedland SJ, Kibel A, et al. Epidemiology and Prevention of Prostate Cancer. *Eur Urol Oncol*. 2021;4(6):877–92. <https://doi.org/10.1016/j.euo.2021.09.006>
2. Lim Ng K. The Etiology of Prostate Cancer. *Exon Publications*; 2021. p. 17–28. <https://doi.org/10.36255/exonpublications.prostatecancer.etiology.2021>
3. Brookman-May SD, Campi R, Henríquez JDS, Klätte T, Langenhuijsen JF, Brausi M, et al. Latest Evidence on the Impact of Smoking, Sports, and Sexual Activity as Modifiable Lifestyle Risk Factors for Prostate Cancer Incidence, Recurrence, and Progression: A Systematic Review of the Literature by the European Association of Urology Section of. *European Urology Focus*. 2019;5(5):756–87. <https://doi.org/10.1016/j.euf.2018.02.007>
4. Gacci M, Russo GI, De Nunzio C, Sebastianelli A, Salvi M, Vignozzi L, et al. Meta-analysis of metabolic syndrome and prostate cancer. *Prostate Cancer and Prostatic Diseases*. 2017;20(2):146–55. <https://doi.org/10.1038/pcan.2017.1>
5. Rider JR, Wilson KM, Sinnott JA, Kelly RS, Mucci LA, Giovannucci EL. Ejaculation Frequency and Risk of Prostate Cancer: Updated Results with an Additional Decade of Follow-up. *European Urology*. 2016;70(6):974–82. <https://doi.org/10.1016/j.eururo.2016.03.027>
6. Trudeau K, Rousseau MC, Parent ME. Extent of Food Processing and Risk of Prostate Cancer: The PROtEuS Study in Montreal, Canada. *Nutrients*. 2020;12(3). <https://doi.org/10.3390/nu12030637>
7. Llahá F, Gil-Lespinard M, Unal P, De Villasante I, Castañeda J, Zamora-Ros R. Consumption of Sweet Beverages and Cancer Risk. A Systematic Review and Meta-Analysis of Observational Studies. *Nutrients*. 2021;13(2):516. <https://doi.org/10.3390/nu13020516>
8. López-Plaza B, Bermejo LM, Santurino C, Cavero-Redondo I, Álvarez-Bueno C, Gómez-Candela C. Milk and Dairy Product Consumption and Prostate Cancer Risk and Mortality: An Overview of Systematic Reviews and Meta-analyses. *Advances in Nutrition*. 2019;10(suppl_2):S212–S23. <https://doi.org/10.1093/advances/nmz014>
9. Naji L, Randhawa H, Sohani Z, Dennis B, Lautenbach D, Kavanagh O, et al. Digital Rectal Examination for Prostate Cancer Screening in Primary Care: A Systematic Review and Meta-Analysis. *The Annals of Family Medicine*. 2018;16(2):149–54. <https://doi.org/10.1370/afm.2205>
10. Stamey TA, Yang N, Hay AR, McNeal JE, Freiha FS, Redwine E. Prostate-specific antigen as a serum marker for adenocarcinoma of the prostate. *N Engl J Med*. 1987;317(15):909–16. <https://doi.org/10.1056/NEJM198710083171501>
11. Mottet N, van den Bergh RCN, Briers E, Van den Broeck T, Cumberbatch MG, De Santis M, et al. EAU-EANM-ESTRO-ESUR-SIOG Guidelines on Prostate Cancer-2020 Update. Part 1: Screening, Diagnosis, and Local Treatment with Curative Intent. *Eur Urol*. 2021;79(2):243–62. <https://doi.org/10.1016/j.eururo.2020.09.042>
12. Albertsen PC. Prostate cancer screening and treatment: where have we come from and where are we going? *BJU International*. 2020;126(2):218–24. <https://doi.org/10.1111/bju.15153>

13. Carter HB, Albertsen PC, Barry MJ, Etzioni R, Freedland SJ, Greene KL, et al. Early Detection of Prostate Cancer: AUA Guideline. *Journal of Urology*. 2013;190(2):419–26. <https://doi.org/10.1016/j.juro.2013.04.119>
14. Fenton JJ, Weyrich MS, Durbin S, Liu Y, Bang H, Melnikow J. Prostate-Specific Antigen-Based Screening for Prostate Cancer. *JAMA*. 2018;319(18):1914. <https://doi.org/10.1001/jama.2018.3712>
15. Parker C, Castro E, Fizazi K, Heidenreich A, Ost P, Procopio G, et al. Prostate cancer: ESMO Clinical Practice Guidelines for diagnosis, treatment and follow-up. *Ann Oncol*. 2020;31(9):1119–34. <https://doi.org/10.1016/j.annonc.2020.06.011>
16. Bjurlin MA, Carroll PR, Eggener S, Fulgham PF, Margolis DJ, Pinto PA, et al. Update of the Standard Operating Procedure on the Use of Multiparametric Magnetic Resonance Imaging for the Diagnosis, Staging and Management of Prostate Cancer. *J Urol*. 2020;203(4):706–12. <https://doi.org/10.1097/JU.0000000000000617>
17. Dickinson L, Ahmed HU, Allen C, Barentsz JO, Carey B, Futterer JJ, et al. Scoring systems used for the interpretation and reporting of multiparametric MRI for prostate cancer detection, localization, and characterization: could standardization lead to improved utilization of imaging within the diagnostic pathway? *Journal of Magnetic Resonance Imaging*. 2013;37(1):48–58. <https://doi.org/10.1002/jmri.23689>
18. Turkbey B, Rosenkrantz AB, Haider MA, Padhani AR, Villeirs G, Macura KJ, et al. Prostate Imaging Reporting and Data System Version 2.1: 2019 Update of Prostate Imaging Reporting and Data System Version 2. *Eur Urol*. 2019;76(3):340–51. <https://doi.org/10.1016/j.eururo.2019.02.033>
19. van Leenders G, van der Kwast TH, Grignon DJ, Evans AJ, Kristiansen G, Kweldam CF, et al. The 2019 International Society of Urological Pathology (ISUP) Consensus Conference on Grading of Prostatic Carcinoma. *Am J Surg Pathol*. 2020;44(8):e87–e99. <https://doi.org/10.1097/PAS.0000000000001497>
20. Egevad L, Delahunt B, Srigley JR, Samaratunga H. International Society of Urological Pathology (ISUP) grading of prostate cancer - An ISUP consensus on contemporary grading. *Apmis*. 2016;124(6):433–5. <https://doi.org/10.1111/apm.12533>
21. Sanda MG, Cadeddu JA, Kirkby E, Chen RC, Crispino T, Fontanarosa J, et al. Clinically Localized Prostate Cancer: AUA/ASTRO/SUO Guideline. Part I: Risk Stratification, Shared Decision Making, and Care Options. *The Journal of urology*. 2018;199(3):683–90. <https://doi.org/10.1016/j.juro.2017.11.095>
22. NICE. Prostate cancer: diagnosis and management [NG131]. National Institute for Health and Care Excellence 2021.
23. Parry MG, Cowling TE, Sujenthiran A, Nossiter J, Berry B, Cathcart P, et al. Risk stratification for prostate cancer management: value of the Cambridge Prognostic Group classification for assessing treatment allocation. *BMC Med*. 2020;18(1):114. <https://doi.org/10.1186/s12916-020-01588-9>
24. Sonnenschein R. The effectiveness of transrectal aspiration cytology in the diagnosis of prostatic cancer. 1975(0302-2838 (Print)). <https://doi.org/10.1159/000455619>
25. Fine SW, Reuter VE. Anatomy of the prostate revisited: implications for prostate biopsy and zonal origins of prostate cancer. *Histopathology*. 2012;60(1):142–52. <https://doi.org/10.1111/j.1365-2559.2011.04004.x>
26. Foo KT. Pathophysiology of clinical benign prostatic hyperplasia. *Asian J Urol*. 2017;4(3):152–7. <https://doi.org/10.1016/j.ajur.2017.06.003>
27. Smith JA, Jr., Scardino PT, Resnick MI, Hernandez AD, Rose SC, Egger MJ. Transrectal ultrasound versus digital rectal examination for the staging of carcinoma of the prostate: results of a prospective, multi-institutional trial. 1997(0022-5347 (Print)). <https://doi.org/10.1097/00005392-199703000-00044>
28. Grups JW, Gruss A, Wirth M, Frohmüller HG. Diagnostic value of transrectal ultrasound in tumor staging and in the detection of incidental prostatic cancer. 1990(0042-1138 (Print)). <https://doi.org/10.1159/000281656>
29. Hodge KK, McNeal JE, Terris MK, Stamey TA. Random systematic versus directed ultrasound guided transrectal core biopsies of the prostate. *J Urol*. 1989;142(1):71–4; discussion 4–5. [https://doi.org/10.1016/S0022-5347\(17\)38664-0](https://doi.org/10.1016/S0022-5347(17)38664-0)
30. Nazir B. Pain during transrectal ultrasound-guided prostate biopsy and the role of periprostatic nerve block: what radiologists should know. *Korean J Radiol*. 2014;15(5):543–53. <https://doi.org/10.3348/kjr.2014.15.5.543>
31. Giannarini G, Autorino R, Valent F, Mgorovich A, Manassero F, De Maria M, et al. Combination of perianal-intrarectal lidocaine-prilocaine cream and periprostatic nerve block for pain

- control during transrectal ultrasound guided prostate biopsy: a randomized, controlled trial. *J Urol.* 2009;181(2):585–91; discussion 91–3. <https://doi.org/10.1016/j.juro.2008.10.002>
32. Bastide C, Lechevallier E, Eghazarian C, Ortega JC, Coulange C. Tolerance of pain during transrectal ultrasound-guided biopsy of the prostate: risk factors. *Prostate Cancer Prostatic Dis.* 2003;6(3):239–41. <https://doi.org/10.1038/sj.pcan.4500664>
 33. Naughton CK, Ornstein DK, Smith DS, Catalona WJ. Pain and morbidity of transrectal ultrasound guided prostate biopsy: a prospective randomized trial of 6 versus 12 cores. *J Urol.* 2000;163(1):168–71. [https://doi.org/10.1016/S0022-5347\(05\)67996-7](https://doi.org/10.1016/S0022-5347(05)67996-7)
 34. Kaver I, Mabjeesh NJ, Matzkin H. Randomized prospective study of periprostatic local anesthesia during transrectal ultrasound-guided prostate biopsy. *Urology.* 2002;59(3):405–8. [https://doi.org/10.1016/S0090-4295\(01\)01538-2](https://doi.org/10.1016/S0090-4295(01)01538-2)
 35. Rodríguez LV, Terris MK. Risks and complications of transrectal ultrasound guided prostate needle biopsy: a prospective study and review of the literature. *J Urol.* 1998;160(6 Pt 1):2115–20. [https://doi.org/10.1016/S0022-5347\(01\)62255-9](https://doi.org/10.1016/S0022-5347(01)62255-9)
 36. Djavan B, Waldert M, Zlotta A, Dobronski P, Seitz C, Remzi M, et al. Safety and morbidity of first and repeat transrectal ultrasound guided prostate needle biopsies: results of a prospective European prostate cancer detection study. *J Urol.* 2001;166(3):856–60. [https://doi.org/10.1016/S0022-5347\(05\)65851-X](https://doi.org/10.1016/S0022-5347(05)65851-X)
 37. Deliveliotis C, John V, Louras G, Andreas S, Alargof E, Sofras F, et al. Multiple transrectal ultrasound guided prostatic biopsies: morbidity and tolerance. *Int Urol Nephrol.* 1999;31(5):681–6. <https://doi.org/10.1023/A:1007168823851>
 38. Irani J, Fournier F, Bon D, Gremmo E, Doré B, Aubert J. Patient tolerance of transrectal ultrasound-guided biopsy of the prostate. *Br J Urol.* 1997;79(4):608–10. <https://doi.org/10.1046/j.1464-410X.1997.00120.x>
 39. Garcia-Perdomo HA, Mejia NG, Fernandez L, Carbonell J. Effectiveness of periprostatic block to prevent pain in transrectal prostate biopsy: a systematic review and a network meta-analysis. *Cent European J Urol.* 2019;72(2):121–33.
 40. Yang Y, Liu Z, Wei Q, Cao D, Yang L, Zhu Y, et al. The Efficiency and Safety of Intrarectal Topical Anesthesia for Transrectal Ultrasound-Guided Prostate Biopsy: A Systematic Review and Meta-Analysis. *Urol Int.* 2017;99(4):373–83. <https://doi.org/10.1159/000481830>
 41. Pradere B, Veeratterapillay R, Dimitropoulos K, Yuan Y, Omar MI, MacLennan S, et al. Nonantibiotic Strategies for the Prevention of Infectious Complications following Prostate Biopsy: A Systematic Review and Meta-Analysis. *J Urol.* 2021;205(3):653–63. <https://doi.org/10.1097/JU.0000000000001399>
 42. Turgut AT, Olçücüoğlu E, Koşar P, Geyik PO, Koşar U. Complications and limitations related to periprostatic local anesthesia before TRUS-guided prostate biopsy. *J Clin Ultrasound.* 2008;36(2):67–71. <https://doi.org/10.1002/jcu.20424>
 43. Ozden E, Yaman O, Göğüş C, Özgencil E, Soygür T. The optimum doses of and injection locations for periprostatic nerve blockade for transrectal ultrasound guided biopsy of the prostate: a prospective, randomized, placebo controlled study. *J Urol.* 2003;170(6 Pt 1):2319–22. <https://doi.org/10.1097/01.ju.0000095760.29931.f7>
 44. Jones JS, Oder M, Zippe CD. Saturation prostate biopsy with periprostatic block can be performed in office. *J Urol.* 2002;168(5):2108–10. [https://doi.org/10.1016/S0022-5347\(05\)64307-8](https://doi.org/10.1016/S0022-5347(05)64307-8)
 45. Nash PA, Bruce JE, Indudhara R, Shinohara K. Transrectal ultrasound guided prostatic nerve blockade eases systematic needle biopsy of the prostate. *J Urol.* 1996;155(2):607–9. [https://doi.org/10.1016/S0022-5347\(01\)66464-4](https://doi.org/10.1016/S0022-5347(01)66464-4)
 46. Nguyen CT, Jones JS. Comparison of traditional basal and apical periprostatic block: impact on injection pain and biopsy pain. *BJU Int.* 2007;99(3):575–8. <https://doi.org/10.1111/j.1464-410X.2006.06652.x>
 47. Kim SJ, Lee J, An DH, Park CH, Lim JH, Kim HG, et al. A randomized controlled comparison between periprostatic nerve block and pelvic plexus block at the base and apex of 14-core prostate biopsies. *World J Urol.* 2019;37(12):2663–9. <https://doi.org/10.1007/s00345-019-02722-w>
 48. Akan H, Yildiz O, Dalva I, Yücesoy C. Comparison of two periprostatic nerve blockade techniques for transrectal ultrasound-guided prostate biopsy: bilateral basal injection and single apical injection. *Urology.* 2009;73(1):23–6. <https://doi.org/10.1016/j.urology.2008.06.066>

49. Philip J, McCabe JE, Roy SD, Samsudin A, Campbell IM, Javle P. Site of local anaesthesia in transrectal ultrasonography-guided 12-core prostate biopsy: does it make a difference? *BJU Int.* 2006;97(2):263–5. <https://doi.org/10.1111/j.1464-410X.2006.05957.x>
50. Torres JP, Rodrigues A, Morais N, Anacleto S, Rodrigues RM, Mota P, et al. Efficacy and safety of a combined anesthetic technique for transrectal prostate biopsy: a single center, prospective, randomized study. *Cent European J Urol.* 2019;72(3):258–62.
51. McCabe JE, Hanchanale VS, Philip J, Javle PM. A randomized controlled trial of topical glyceryl trinitrate before transrectal ultrasonography-guided biopsy of the prostate. *BJU Int.* 2007;100(3):536–8; discussion 8–9. <https://doi.org/10.1111/j.1464-410X.2007.06990.x>
52. Skriapas K, Konstantinidis C, Samarinas M, Xanthis S, Gekas A. Comparison between lidocaine and glyceryl trinitrate ointment for perianal-intrarectal local anesthesia before transrectal ultrasonography-guided prostate biopsy: a placebo-controlled trial. *Urology.* 2011;77(4):905–8. <https://doi.org/10.1016/j.urology.2010.09.065>
53. Stefanova V, Buckley R, Flax S, Spevack L, Hajek D, Tunis A, et al. Transperineal Prostate Biopsies Using Local Anesthesia: Experience with 1,287 Patients. Prostate Cancer Detection Rate, Complications and Patient Tolerability. *J Urol.* 2019;201(6):1121–6. <https://doi.org/10.1097/JU.000000000000156>
54. Lopez JF, Campbell A, Omer A, Stroman L, Bondad J, Austin T, et al. Local anaesthetic transperineal (LATP) prostate biopsy using a probe-mounted transperineal access system: a multicentre prospective outcome analysis. *BJU Int.* 2021;128(3):311–8. <https://doi.org/10.1111/bju.15337>
55. Tyloch JF, Wieczorek AP. The standards of an ultrasound examination of the prostate gland. Part 1. *J Ultrasound.* 2016;16(67):378–90. <https://doi.org/10.15557/JoU.2016.0038>
56. Paul R, Korzinek C, Necknig U, Niesel T, Alschibaja M, Leyh H, et al. Influence of transrectal ultrasound probe on prostate cancer detection in transrectal ultrasound-guided sextant biopsy of prostate. *Urology.* 2004;64(3):532–6. <https://doi.org/10.1016/j.urology.2004.04.005>
57. Ismail MT, Gomella LG. Transrectal prostate biopsy. *Urol Clin North Am.* 2013;40(4):457–72. <https://doi.org/10.1016/j.ucl.2013.07.012>
58. Ching CB, Moussa AS, Li J, Lane BR, Zippe C, Jones JS. Does transrectal ultrasound probe configuration really matter? End fire versus side fire probe prostate cancer detection rates. *J Urol.* 2009;181(5):2077–82; discussion 82–3. <https://doi.org/10.1016/j.juro.2009.01.035>
59. Raber M, Scattoni V, Gallina A, Freschi M, De Almeyda EP, Girolamo VD, et al. Does the transrectal ultrasound probe influence prostate cancer detection in patients undergoing an extended prostate biopsy scheme? Results of a large retrospective study. *BJU Int.* 2012;109(5):672–7. <https://doi.org/10.1111/j.1464-410X.2011.10522.x>
60. Rom M, Pycha A, Wiunig C, Reissigl A, Waldert M, Klatt T, et al. Prospective randomized multicenter study comparing prostate cancer detection rates of end-fire and side-fire transrectal ultrasound probe configuration. *Urology.* 2012;80(1):15–8. <https://doi.org/10.1016/j.urology.2012.01.061>
61. van der Slot MA, Leijte JAP, van der Schoot DKE, Oomens E, Roemeling S. End-fire versus side-fire: a randomized controlled study of transrectal ultrasound guided biopsies for prostate cancer detection. *Scand J Urol.* 2020;54(2):101–4. <https://doi.org/10.1080/21681805.2020.1738544>
62. Owoeyo OB, Ayegbusi AL, Akinbo SA, Ogunsola MO. Biopsy gun-driven versus manually-driven tru-cut prostate biopsy; any difference in the yield? Ilorin experience. *Niger Postgrad Med J.* 2011;18(1):48–50.
63. Ragde H, Aldape HC, Bagley CM, Jr. Ultrasound-guided prostate biopsy. Biopsy gun superior to aspiration. *Urology.* 1988;32(6):503–6. [https://doi.org/10.1016/S0090-4295\(98\)90029-2](https://doi.org/10.1016/S0090-4295(98)90029-2)
64. Patel AR, Jones JS. The prostate needle biopsy gun: busting a myth. *J Urol.* 2007;178(2):683–5. <https://doi.org/10.1016/j.juro.2007.03.090>
65. Kaye KW. Prostate biopsy using automatic gun. Technique for determination of precise biopsy site. *Urology.* 1989;34(2):111–2. [https://doi.org/10.1016/0090-4295\(89\)90177-5](https://doi.org/10.1016/0090-4295(89)90177-5)
66. Fiset PO, Aprikian A, Brimo F. Length of prostate biopsy cores: does it impact cancer detection? *Can J Urol.* 2013;20(4):6848–53.
67. Ergun M, Islamoglu E, Yalcinkaya S, Tokgoz H, Savas M. Does length of prostate biopsy cores have an impact on diagnosis of prostate cancer? *Turk J Urol.* 2016;42(3):130–3. <https://doi.org/10.5152/tud.2016.78700>

68. Obek C, Doganca T, Erdal S, Erdogan S, Durak H. Core length in prostate biopsy: size matters. *J Urol*. 2012;187(6):2051–5. <https://doi.org/10.1016/j.juro.2012.01.075>
69. Dell'Atti L, Ippolito C. The impact of core length on prostate cancer diagnosis during a standard 14-core prostate biopsy scheme. *Urologia*. 2016;83(4):186–9. <https://doi.org/10.5301/uro.5000199>
70. Cicione A, Cantiello F, De Nunzio C, Tubaro A, Damiano R. Prostate biopsy quality is independent of needle size: a randomized single-center prospective study. *Urol Int*. 2012;89(1):57–60. <https://doi.org/10.1159/000339250>
71. Cicione A, Cantiello F, De Nunzio C, Tubaro A, Damiano R. Needle biopsy size and pathological Gleason Score diagnosis: No evidence for a link. *Can Urol Assoc J*. 2013;7(9–10):E567–71. <https://doi.org/10.5489/cuaj.311>
72. Li ADR, Plott J, Chen L, Montgomery JS, Shih A. Needle deflection and tissue sampling length in needle biopsy. *J Mech Behav Biomed Mater*. 2020;104:103632. <https://doi.org/10.1016/j.jmbm.2020.103632>
73. Stone NN, Mouraviev V, Schechter D, Goetz J, Lucia MS, Smith EE, et al. Deflection Analysis of Different Needle Designs for Prostate Biopsy and Focal Therapy. *Technol Cancer Res Treat*. 2017;16(5):654–61. <https://doi.org/10.1177/1533034616671007>
74. Vis AN, Boerma MO, Ciatto S, Hoedemaeker RF, Schroder FH, van der Kwast TH. Detection of prostate cancer: a comparative study of the diagnostic efficacy of sextant transrectal versus sextant transperineal biopsy. *Urology*. 2000;56(4):617–21. [https://doi.org/10.1016/S0090-4295\(00\)00681-6](https://doi.org/10.1016/S0090-4295(00)00681-6)
75. Cowan T, Baker E, McCray G, Reeves F, Houlihan K, Johns-Putra L. Detection of clinically significant cancer in the anterior prostate by transperineal biopsy. *BJU Int*. 2020;126 Suppl 1:33–7. <https://doi.org/10.1111/bju.15124>
76. Rai BP, Mayerhofer C, Somani BK, Kallidonis P, Nagele U, Tokas T. Magnetic Resonance Imaging/Ultrasound Fusion-guided Transperineal Versus Magnetic Resonance Imaging/Ultrasound Fusion-guided Transrectal Prostate Biopsy-A Systematic Review. *Eur Urol Oncol*. 2021;4(6):904–13. <https://doi.org/10.1016/j.euo.2020.12.012>
77. Hong YM, Lai FC, Chon CH, McNeal JE, Presti JC, Jr. Impact of prior biopsy scheme on pathologic features of cancers detected on repeat biopsies. *Urol Oncol*. 2004;22(1):7–10. [https://doi.org/10.1016/S1078-1439\(03\)00147-9](https://doi.org/10.1016/S1078-1439(03)00147-9)
78. Rabbani F, Stroumbakis N, Kava BR, Cookson MS, Fair WR. Incidence and clinical significance of false-negative sextant prostate biopsies. *J Urol*. 1998;159(4):1247–50. [https://doi.org/10.1016/S0022-5347\(01\)63574-2](https://doi.org/10.1016/S0022-5347(01)63574-2)
79. Norberg M, Egevad L, Holmberg L, Sparén P, Norlén BJ, Busch C. The sextant protocol for ultrasound-guided core biopsies of the prostate underestimates the presence of cancer. *Urology*. 1997;50(4):562–6. [https://doi.org/10.1016/S0090-4295\(97\)00306-3](https://doi.org/10.1016/S0090-4295(97)00306-3)
80. Levine MA, Ittman M, Melamed J, Lepor H. Two consecutive sets of transrectal ultrasound guided sextant biopsies of the prostate for the detection of prostate cancer. *J Urol*. 1998;159(2):471–5; discussion 5–6. [https://doi.org/10.1016/S0022-5347\(01\)63951-X](https://doi.org/10.1016/S0022-5347(01)63951-X)
81. Taneja SSBM, Carter HB, Schellhammer P, Cookson MS, Gomella LG, Troyer D, et al. White Paper: AUA/Optimal Techniques of Prostate Biopsy and Specimen Handling <http://www.auanet.org/common/pdf/education/clinicalguidance/Prostate-Biopsy-WhitePaper.pdf>. 2013 [
82. Eichler K, Hempel S, Wilby J, Myers L, Bachmann LM, Kleijnen J. Diagnostic value of systematic biopsy methods in the investigation of prostate cancer: a systematic review. *J Urol*. 2006;175(5):1605–12. [https://doi.org/10.1016/S0022-5347\(05\)00957-2](https://doi.org/10.1016/S0022-5347(05)00957-2)
83. Ghafouri M, Velayati M, Aliyari Ghasabeh M, Shakiba M, Alavi M. Prostate Biopsy Using Transrectal Ultrasonography; The Optimal Number of Cores Regarding Cancer Detection Rate and Complications. *Iran J Radiol*. 2015;12(2):e13257. <https://doi.org/10.5812/iranradiol.13257>
84. Shariat SF, Roehrborn CG. Using biopsy to detect prostate cancer. *Rev Urol*. 2008;10(4):262–80.
85. Stewart CS, Leibovich BC, Weaver AL, Lieber MM. Prostate cancer diagnosis using a saturation needle biopsy technique after previous negative sextant biopsies. *J Urol*. 2001;166(1):86–91; discussion -2. [https://doi.org/10.1016/S0022-5347\(05\)66083-1](https://doi.org/10.1016/S0022-5347(05)66083-1)
86. Hu Y, Ahmed HU, Carter T, Arumainayagam N, Lecornet E, Barzell W, et al. A biopsy simulation study to assess the accuracy of several transrectal ultrasonography (TRUS)-biopsy strategies compared with

- template prostate mapping biopsies in patients who have undergone radical prostatectomy. *BJU Int.* 2012;110(6):812–20. <https://doi.org/10.1111/j.1464-410X.2012.10933.x>
87. Kuru TH, Wadhwa K, Chang RT, Echeverria LM, Roethke M, Polson A, et al. Definitions of terms, processes and a minimum dataset for transperineal prostate biopsies: a standardization approach of the Ginsburg Study Group for Enhanced Prostate Diagnostics. *BJU Int.* 2013;112(5):568–77. <https://doi.org/10.1111/bju.12132>
 88. Hansen N, Patrino G, Wadhwa K, Gaziev G, Miano R, Barrett T, et al. Magnetic Resonance and Ultrasound Image Fusion Supported Transperineal Prostate Biopsy Using the Ginsburg Protocol: Technique, Learning Points, and Biopsy Results. *Eur Urol.* 2016;70(2):332–40. <https://doi.org/10.1016/j.eururo.2016.02.064>
 89. Gunzel K, Magheli A, Baco E, Cash H, Heinrich S, Neubert H, et al. Infection rate and complications after 621 transperineal MRI-TRUS fusion biopsies in local anesthesia without standard antibiotic prophylaxis. *World J Urol.* 2021;39(10):3861–6. <https://doi.org/10.1007/s00345-021-03699-1>
 90. Huang GL, Kang CH, Lee WC, Chiang PH. Comparisons of cancer detection rate and complications between transrectal and transperineal prostate biopsy approaches - a single center preliminary study. *BMC Urol.* 2019;19(1):101. <https://doi.org/10.1186/s12894-019-0539-4>
 91. Urkmez A, Demirel C, Altok M, Bathala TK, Shapiro DD, Davis JW. Freehand versus Grid-Based Transperineal Prostate Biopsy: A Comparison of Anatomical Region Yield and Complications. *J Urol.* 2021;206(4):894–902. <https://doi.org/10.1097/JU.0000000000001902>
 92. Sivaraman A, Ramasamy V, Aarthy P, Sankar V, Sivaraman PB. Safety and feasibility of free-hand transperineal prostate biopsy under local anesthesia: Our initial experience. *Indian J Urol.* 2022;38(1):34–41.
 93. Marra G, Marquis A, Tappero S, D'Agate D, Oderda M, Callaris G, et al. Transperineal Free-hand mpMRI Fusion-targeted Biopsies Under Local Anesthesia: Technique and Feasibility From a Single-center Prospective Study. *Urology.* 2020;140:122–31. <https://doi.org/10.1016/j.urology.2019.11.078>
 94. Xiang J, Yan H, Li J, Wang X, Chen H, Zheng X. Transperineal versus transrectal prostate biopsy in the diagnosis of prostate cancer: a systematic review and meta-analysis. *World J Surg Oncol.* 2019;17(1):31. <https://doi.org/10.1186/s12957-019-1573-0>
 95. Wetterauer C, Shahin O, Federer-Gsponer JR, Keller N, Wyler S, Seifert HH, et al. Feasibility of free-hand MRI/US cognitive fusion transperineal biopsy of the prostate in local anaesthesia as in-office procedure-experience with 400 patients. *Prostate Cancer Prostatic Dis.* 2020;23(3):429–34. <https://doi.org/10.1038/s41391-019-0201-y>
 96. Bass EJ, Donaldson IA, Freeman A, Jameson C, Punwani S, Moore C, et al. Magnetic resonance imaging targeted transperineal prostate biopsy: a local anaesthetic approach. *Prostate Cancer Prostatic Dis.* 2017;20(3):311–7. <https://doi.org/10.1038/pcan.2017.13>
 97. Guo LH, Wu R, Xu HX, Xu JM, Wu J, Wang S, et al. Comparison between Ultrasound Guided Transperineal and Transrectal Prostate Biopsy: A Prospective, Randomized, and Controlled Trial. *Sci Rep.* 2015;5:16089. <https://doi.org/10.1038/srep16089>
 98. Egawa S, Wheeler TM, Greene DR, Scardino PT. Unusual hyperechoic appearance of prostate cancer on transrectal ultrasonography. *Br J Urol.* 1992;69(2):169–74. <https://doi.org/10.1111/j.1464-410X.1992.tb15490.x>
 99. Dahmert WF, Hamper UM, Eggleston JC, Walsh PC, Sanders RC. Prostatic evaluation by transrectal sonography with histopathologic correlation: the echogenic appearance of early carcinoma. *Radiology.* 1986;158(1):97–102. <https://doi.org/10.1148/radiology.158.1.3510032>
 100. Noh TI, Shin YS, Shim JS, Yoon JH, Kim JH, Bae JH, et al. Are hypoechoic lesions on transrectal ultrasonography a marker for clinically significant prostate cancer? *Korean J Urol.* 2013;54(10):666–70. <https://doi.org/10.4111/kju.2013.54.10.666>
 101. Sharma M, Nerli RB, Nutalapati SH, Ghagane SC. Hypoechoic lesions on Transrectal Ultrasound and its correlation to Gleason grade in the diagnosis of Clinically Significant Prostate Cancer: A Prospective Study. *South Asian J Cancer.* 2021;10(3):155–60. <https://doi.org/10.1055/s-0041-1731906>
 102. Onur R, Litttrup PJ, Pontes JE, Bianco FJ, Jr. Contemporary impact of transrectal ultrasound lesions for prostate cancer detection. *J Urol.* 2004;172(2):512–4. <https://doi.org/10.1097/01.ju.0000131621.61732.6b>

103. Toi A, Neill MG, Lockwood GA, Sweet JM, Tammsalu LA, Fleshner NE. The continuing importance of transrectal ultrasound identification of prostatic lesions. *J Urol.* 2007;177(2):516–20. <https://doi.org/10.1016/j.juro.2006.09.061>
104. Gosselaar C, Roobol MJ, Roemeling S, Wolters T, van Leenders GJ, Schroder FH. The value of an additional hypoechoic lesion-directed biopsy core for detecting prostate cancer. *BJU Int.* 2008;101(6):685–90. <https://doi.org/10.1111/j.1464-410X.2007.07309.x>
105. Shakir NA, Siddiqui MM, George AK, Kongnyuy M, Ho R, Fascelli M, et al. Should Hypoechoic Lesions on Transrectal Ultrasound Be Sampled During Magnetic Resonance Imaging-targeted Prostate Biopsy? *Urology.* 2017;105:113–7. <https://doi.org/10.1016/j.urology.2016.11.012>
106. Goldberg H, Ahmad AE, Chandrasekar T, Klotz L, Emberton M, Haider MA, et al. Comparison of Magnetic Resonance Imaging and Transrectal Ultrasound Informed Prostate Biopsy for Prostate Cancer Diagnosis in Biopsy Naive Men: A Systematic Review and Meta-Analysis. *J Urol.* 2020;203(6):1085–93. <https://doi.org/10.1097/JU.0000000000000595>
107. Baccaglini W, Glina FPA, Pazeto CL, Bernardo WM, Sanchez-Salas R. mpMRI-targeted biopsy versus systematic biopsy for clinically significant prostate cancer diagnosis: a systematic review and meta-analysis. *Curr Opin Urol.* 2020;30(5):711–9. <https://doi.org/10.1097/MOU.0000000000000801>
108. Kasivisvanathan V, Rannikko AS, Borghi M, Panebianco V, Mynderse LA, Vaarala MH, et al. MRI-Targeted or Standard Biopsy for Prostate-Cancer Diagnosis. *N Engl J Med.* 2018;378(19):1767–77. <https://doi.org/10.1056/NEJMoa1801993>
109. Washino S, Kobayashi S, Okochi T, Kameda T, Konoshi T, Miyagawa T, et al. Cancer detection rate of prebiopsy MRI with subsequent systematic and targeted biopsy are superior to non-targeting systematic biopsy without MRI in biopsy naive patients: a retrospective cohort study. *BMC Urol.* 2018;18(1):51. <https://doi.org/10.1186/s12894-018-0361-4>
110. Woo S, Suh CH, Eastham JA, Zelefsky MJ, Morris MJ, Abida W, et al. Comparison of Magnetic Resonance Imaging-stratified Clinical Pathways and Systematic Transrectal Ultrasound-guided Biopsy Pathway for the Detection of Clinically Significant Prostate Cancer: A Systematic Review and Meta-analysis of Randomized Controlled Trials. *Eur Urol Oncol.* 2019;2(6):605–16. <https://doi.org/10.1016/j.euo.2019.05.004>
111. Drost FH, Osses DF, Nieboer D, Steyerberg EW, Bangma CH, Roobol MJ, et al. Prostate MRI, with or without MRI-targeted biopsy, and systematic biopsy for detecting prostate cancer. *Cochrane Database Syst Rev.* 2019;4:CD012663. <https://doi.org/10.1002/14651858.CD012663.pub2>
112. Klotz L, Chin J, Black PC, Finelli A, Anidjar M, Bladou F, et al. Comparison of Multiparametric Magnetic Resonance Imaging-Targeted Biopsy With Systematic Transrectal Ultrasonography Biopsy for Biopsy-Naive Men at Risk for Prostate Cancer: A Phase 3 Randomized Clinical Trial. *JAMA Oncol.* 2021;7(4):534–42. <https://doi.org/10.1001/jamaoncol.2020.7589>
113. Rouviere O, Puech P, Renard-Penna R, Claudon M, Roy C, Mege-Lechevallier F, et al. Use of prostate systematic and targeted biopsy on the basis of multiparametric MRI in biopsy-naive patients (MRI-FIRST): a prospective, multicentre, paired diagnostic study. *Lancet Oncol.* 2019;20(1):100–9. [https://doi.org/10.1016/S1470-2045\(18\)30569-2](https://doi.org/10.1016/S1470-2045(18)30569-2)
114. Ahdoot M, Wilbur AR, Reese SE, Lebastchi AH, Mehralivand S, Gomella PT, et al. MRI-Targeted, Systematic, and Combined Biopsy for Prostate Cancer Diagnosis. *N Engl J Med.* 2020;382(10):917–28. <https://doi.org/10.1056/NEJMoa1910038>
115. van der Leest M, Cornel E, Israel B, Hendriks R, Padhani AR, Hoogenboom M, et al. Head-to-head Comparison of Transrectal Ultrasound-guided Prostate Biopsy Versus Multiparametric Prostate Resonance Imaging with Subsequent Magnetic Resonance-guided Biopsy in Biopsy-naive Men with Elevated Prostate-specific Antigen: A Large Prospective Multicenter Clinical Study. *Eur Urol.* 2019;75(4):570–8. <https://doi.org/10.1016/j.eururo.2018.11.023>
116. Filson CP, Natarajan S, Margolis DJ, Huang J, Lieu P, Dorey FJ, et al. Prostate cancer detection with magnetic resonance-ultrasound fusion biopsy: The role of systematic and targeted biopsies. *Cancer.* 2016;122(6):884–92. <https://doi.org/10.1002/cncr.29874>
117. Maxeiner A, Kittner B, Blobel C, Wiemer L, Hofbauer SL, Fischer T, et al. Primary magnetic resonance imaging/ultrasonography fusion-guided biopsy of the prostate. *BJU Int.* 2018;122(2):211–8. <https://doi.org/10.1111/bju.14212>

118. Elkhoury FF, Felker ER, Kwan L, Sisk AE, Delfin M, Natarajan S, et al. Comparison of Targeted vs Systematic Prostate Biopsy in Men Who Are Biopsy Naive: The Prospective Assessment of Image Registration in the Diagnosis of Prostate Cancer (PAIREDCAP) Study. *JAMA Surg.* 2019;154(9):811–8. <https://doi.org/10.1001/jamasurg.2019.1734>
119. Tu X, Lin T, Cai D, Liu Z, Yang L, Wei Q. The optimal core number and site for MRI-targeted biopsy of prostate? A systematic review and pooled analysis. *Minerva Urol Nefrol.* 2020;72(2):144–51. <https://doi.org/10.23736/S0393-2249.20.03639-5>
120. Ahmed HU, El-Shater Bosaily A, Brown LC, Gabe R, Kaplan R, Parmar MK, et al. Diagnostic accuracy of multi-parametric MRI and TRUS biopsy in prostate cancer (PROMIS): a paired validating confirmatory study. *Lancet.* 2017;389(10071):815–22. [https://doi.org/10.1016/S0140-6736\(16\)32401-1](https://doi.org/10.1016/S0140-6736(16)32401-1)
121. Oishi M, Shin T, Ohe C, Nassiri N, Palmer SL, Aron M, et al. Which Patients with Negative Magnetic Resonance Imaging Can Safely Avoid Biopsy for Prostate Cancer? *J Urol.* 2019;201(2):268–76. <https://doi.org/10.1016/j.juro.2018.08.046>
122. Hale GR, Czarniecki M, Cheng A, Bloom JB, Seifabadi R, Gold SA, et al. Comparison of Elastic and Rigid Registration during Magnetic Resonance Imaging/Ultrasound Fusion-Guided Prostate Biopsy: A Multi-Operator Phantom Study. *J Urol.* 2018;200(5):1114–21. <https://doi.org/10.1016/j.juro.2018.06.028>
123. Venderink W, de Rooij M, Sedelaar JPM, Huisman HJ, Futterer JJ. Elastic Versus Rigid Image Registration in Magnetic Resonance Imaging-transrectal Ultrasound Fusion Prostate Biopsy: A Systematic Review and Meta-analysis. *Eur Urol Focus.* 2018;4(2):219–27. <https://doi.org/10.1016/j.euf.2016.07.003>
124. Hanske J, Risse Y, Roghmann F, Pucheril D, Berg S, Tully KH, et al. Comparison of prostate cancer detection rates in patients undergoing MRI/TRUS fusion prostate biopsy with two different software-based systems. *Prostate.* 2022;82(2):227–34. <https://doi.org/10.1002/pros.24264>
125. Stabile A, Dell'Oglio P, Gandaglia G, Fossati N, Brembilla G, Cristel G, et al. Not All Multiparametric Magnetic Resonance Imaging-targeted Biopsies Are Equal: The Impact of the Type of Approach and Operator Expertise on the Detection of Clinically Significant Prostate Cancer. *Eur Urol Oncol.* 2018;1(2):120–8. <https://doi.org/10.1016/j.euo.2018.02.002>
126. Cata ED, Van Praet C, Andras I, Kadula P, Ognean R, Buzoianu M, et al. Analyzing the learning curves of a novice and an experienced urologist for transrectal magnetic resonance imaging-ultrasound fusion prostate biopsy. *Transl Androl Urol.* 2021;10(5):1956–65. <https://doi.org/10.21037/tau-21-8>
127. Derigs F, Doryumu S, Tollens F, Norenberg D, Neuberger M, von Hardenberg J, et al. A prospective study on inter-operator variability in semi-robotic software-based MRI/TRUS-fusion targeted prostate biopsies. *World J Urol.* 2022;40(2):427–33. <https://doi.org/10.1007/s00345-021-03891-3>
128. Pepe P, Garufi A, Priolo GD, Pennisi M. Multiparametric MRI/TRUS Fusion Prostate Biopsy: Advantages of a Transperineal Approach. *Anticancer Res.* 2017;37(6):3291–4. <https://doi.org/10.21873/anticancer.11695>
129. Loy LM, Lim GH, Leow JJ, Lee CH, Tan TW, Tan CH. A systematic review and meta-analysis of magnetic resonance imaging and ultrasound guided fusion biopsy of prostate for cancer detection-Comparing transrectal with transperineal approaches. *Urol Oncol.* 2020;38(8):650–60. <https://doi.org/10.1016/j.urolonc.2020.04.005>
130. Venderink W, Bomers JG, Overduin CG, Padhani AR, de Lauw GR, Sedelaar MJ, et al. Multiparametric Magnetic Resonance Imaging for the Detection of Clinically Significant Prostate Cancer: What Urologists Need to Know. Part 3: Targeted Biopsy. *Eur Urol.* 2020;77(4):481–90. <https://doi.org/10.1016/j.eururo.2019.10.009>
131. Overduin CG, Futterer JJ, Barentsz JO. MRI-guided biopsy for prostate cancer detection: a systematic review of current clinical results. *Curr Urol Rep.* 2013;14(3):209–13. <https://doi.org/10.1007/s11934-013-0323-z>
132. Pondman KM, Futterer JJ, ten Haken B, Schultze Kool LJ, Witjes JA, Hambroek T, et al. MR-guided biopsy of the prostate: an overview of techniques and a systematic review. *Eur Urol.* 2008;54(3):517–27. <https://doi.org/10.1016/j.eururo.2008.06.001>
133. Wegelin O, Exterkate L, van der Leest M, Kummer JA, Vreuls W, de Bruin PC, et al. The FUTURE Trial: A Multicenter Randomised Controlled Trial on Target Biopsy Techniques Based on Magnetic Resonance Imaging in the Diagnosis of Prostate Cancer in Patients with Prior Negative Biopsies. *Eur Urol.* 2019;75(4):582–90. <https://doi.org/10.1016/j.eururo.2018.11.040>

134. Costa DN, Goldberg K, Leon AD, Lotan Y, Xi Y, Aziz M, et al. Magnetic Resonance Imaging-guided In-bore and Magnetic Resonance Imaging-transrectal Ultrasound Targeted Prostate Biopsies: An Adjusted Comparison of Clinically Significant Prostate Cancer Detection Rate. *Eur Urol Oncol.* 2019;2(4):397–404. <https://doi.org/10.1016/j.euo.2018.08.022>
135. Bass EJ, Pantovic A, Connor MJ, Loeb S, Rastinehad AR, Winkler M, et al. Diagnostic accuracy of magnetic resonance imaging targeted biopsy techniques compared to transrectal ultrasound guided biopsy of the prostate: a systematic review and meta-analysis. *Prostate Cancer Prostatic Dis.* 2021. <https://doi.org/10.1038/s41391-021-00449-7>
136. Watts KL, Frechette L, Muller B, Ilinky D, Kovac E, Sankin A, et al. Systematic review and meta-analysis comparing cognitive vs. image-guided fusion prostate biopsy for the detection of prostate cancer. *Urol Oncol.* 2020;38(9):734 e19–e25. <https://doi.org/10.1016/j.urolonc.2020.03.020>
137. Jager A, Vilanova JC, Michi M, Wijkstra H, Oddens JR. The challenge of prostate biopsy guidance in the era of mpMRI detected lesion: ultrasound-guided versus in-bore biopsy. *Br J Radiol.* 2022;95(1131):20210363. <https://doi.org/10.1259/bjr.20210363>
138. Meier-Schroers M, Homsí R, Kukuk G, Wolter K, Decker G, Fischer S, et al. In-bore transrectal MRI-guided prostate biopsies: Are there risk factors for complications? *Eur J Radiol.* 2016;85(12):2169–73. <https://doi.org/10.1016/j.ejrad.2016.09.029>
139. Queiroz MRG, Falsarella PM, Mariotti GC, Lemos GC, Baroni RH, Mussi TC, et al. Comparison of complications rates between multiparametric magnetic resonance imaging-transrectal ultrasound (TRUS) fusion and systematic TRUS prostatic biopsies. *Abdom Radiol (NY).* 2019;44(2):732–8. <https://doi.org/10.1007/s00261-018-1782-y>
140. Altok M, Kim B, Patel BB, Shih YT, Ward JF, McRae SE, et al. Cost and efficacy comparison of five prostate biopsy modalities: a platform for integrating cost into novel-platform comparative research. *Prostate Cancer Prostatic Dis.* 2018;21(4):524–32. <https://doi.org/10.1038/s41391-018-0056-7>
141. Maris B, Tenga C, Vicario R, Palladino L, Murr N, De Piccoli M, et al. Toward autonomous robotic prostate biopsy: a pilot study. *Int J Comput Assist Radiol Surg.* 2021;16(8):1393–401. <https://doi.org/10.1007/s11548-021-02437-7>
142. Kroenig M, Schaal K, Benndorf M, Soschynski M, Lenz P, Krauss T, et al. Diagnostic Accuracy of Robot-Guided, Software Based Transperineal MRI/TRUS Fusion Biopsy of the Prostate in a High Risk Population of Previously Biopsy Negative Men. *Biomed Res Int.* 2016;2016:2384894. <https://doi.org/10.1155/2016/2384894>
143. Wetterauer C, Trotsenko P, Matthias MO, Breit C, Keller N, Meyer A, et al. Diagnostic accuracy and clinical implications of robotic assisted MRI-US fusion guided target saturation biopsy of the prostate. *Sci Rep.* 2021;11(1):20250. <https://doi.org/10.1038/s41598-021-99854-0>
144. Mischinger J, Kaufmann S, Russo GI, Harland N, Rausch S, Amend B, et al. Targeted vs systematic robot-assisted transperineal magnetic resonance imaging-transrectal ultrasonography fusion prostate biopsy. *BJU Int.* 2018;121(5):791–8. <https://doi.org/10.1111/bju.14089>
145. Lee AYM, Yang XY, Lee HJ, Law YM, Huang HH, Lau WKO, et al. Multiparametric MRI-ultrasonography software fusion prostate biopsy: initial results using a stereotactic robotic-assisted transperineal prostate biopsy platform comparing systematic vs targeted biopsy. *BJU Int.* 2020;126(5):568–76. <https://doi.org/10.1111/bju.15118>
146. Yang X, Lee AY, Law YM, Sim ASP, Tay KJ, Lau WKO, et al. Stereotactic robot-assisted transperineal prostate biopsy under local anaesthesia and sedation: moving robotic biopsy from operating theatre to clinic. *J Robot Surg.* 2020;14(5):767–72. <https://doi.org/10.1007/s11701-020-01052-z>
147. Patel MI, Mutter S, Vladica P, Gillatt D. Robotic-assisted magnetic resonance imaging ultrasound fusion results in higher significant cancer detection compared to cognitive prostate targeting in biopsy naive men. *Transl Androl Urol.* 2020;9(2):601–8. <https://doi.org/10.21037/tau.2020.01.33>
148. Barral M, Lefevre A, Camparo P, Hoogenboom M, Pierre T, Soyer P, et al. In-Bore Transrectal MRI-Guided Biopsy With Robotic Assistance in the Diagnosis of Prostate Cancer: An Analysis of 57 Patients. *AJR Am J Roentgenol.* 2019;213(4):W171–W9. <https://doi.org/10.2214/AJR.19.21145>
149. Vilanova JC, Perez de Tudela A, Puig J, Hoogenboom M, Barcelo J, Planas M, et al. Robotic-assisted transrectal MRI-guided biopsy. Technical feasibility and role in the current diagnosis of prostate cancer: an initial single-center experience. *Abdom Radiol (NY).* 2020;45(12):4150–9. <https://doi.org/10.1007/s00261-020-02665-6>

150. Bomers JGR, Bosboom DGH, Tigelaar GH, Sabisch J, Futterer JJ, Yakar D. Feasibility of a 2(nd) generation MR-compatible manipulator for transrectal prostate biopsy guidance. *Eur Radiol.* 2017;27(4):1776–82. <https://doi.org/10.1007/s00330-016-4504-2>
151. Linder N, Schaudinn A, Petersen TO, Bailis N, Stumpp P, Horn LC, et al. In-bore biopsies of the prostate assisted by a remote-controlled manipulator at 1.5 T. *MAGMA.* 2019;32(5):599–605. <https://doi.org/10.1007/s10334-019-00751-5>
152. Johansen TEB, Zahl PH, Baco E, Bartoletti R, Bonkat G, Bruyere F, et al. Antibiotic resistance, hospitalizations, and mortality related to prostate biopsy: first report from the Norwegian Patient Registry. *World J Urol.* 2020;38(1):17–26. <https://doi.org/10.1007/s00345-019-02837-0>
153. Loeb S, van den Heuvel S, Zhu X, Bangma CH, Schroder FH, Roobol MJ. Infectious complications and hospital admissions after prostate biopsy in a European randomized trial. *Eur Urol.* 2012;61(6):1110–4. <https://doi.org/10.1016/j.eururo.2011.12.058>
154. Bruyere F, Malavaud S, Bertrand P, Decock A, Cariou G, Doublet JD, et al. Probiotate: a multicenter, prospective analysis of infectious complications after prostate biopsy. *J Urol.* 2015;193(1):145–50. <https://doi.org/10.1016/j.juro.2014.07.086>
155. Wagenlehner FM, van Oostrum E, Tenke P, Tandogdu Z, Cek M, Grabe M, et al. Infective complications after prostate biopsy: outcome of the Global Prevalence Study of Infections in Urology (GPIU) 2010 and 2011, a prospective multinational multicentre prostate biopsy study. *Eur Urol.* 2013;63(3):521–7. <https://doi.org/10.1016/j.eururo.2012.06.003>
156. Batura D, Gopal Rao G. The national burden of infections after prostate biopsy in England and Wales: a wake-up call for better prevention. *J Antimicrob Chemother.* 2013;68(2):247–9. <https://doi.org/10.1093/jac/dks401>
157. Patel U, Dasgupta P, Amoroso P, Challacombe B, Pilcher J, Kirby R. Infection after transrectal ultrasonography-guided prostate biopsy: increased relative risks after recent international travel or antibiotic use. *BJU Int.* 2012;109(12):1781–5. <https://doi.org/10.1111/j.1464-410X.2011.10561.x>
158. Roberts MJ, Bennett HY, Harris PN, Holmes M, Grummet J, Naber K, et al. Prostate Biopsy-related Infection: A Systematic Review of Risk Factors, Prevention Strategies, and Management Approaches. *Urology.* 2017;104:11–21. <https://doi.org/10.1016/j.urology.2016.12.011>
159. Zani EL, Clark OA, Rodrigues Netto N, Jr. Antibiotic prophylaxis for transrectal prostate biopsy. *Cochrane Database Syst Rev.* 2011(5):CD006576. <https://doi.org/10.1002/14651858.CD006576.pub2>
160. Klemann N, Helgstrand JT, Brasso K, Vainer B, Iversen P, Roder MA. Antibiotic prophylaxis and complications following prostate biopsies - a systematic review. *Dan Med J.* 2017;64(1).
161. Pilatz A, Dimitropoulos K, Veeratterapillay R, Yuan Y, Omar MI, MacLennan S, et al. Antibiotic Prophylaxis for the Prevention of Infectious Complications following Prostate Biopsy: A Systematic Review and Meta-Analysis. *J Urol.* 2020;204(2):224–30. <https://doi.org/10.1097/JU.0000000000000814>
162. Roberts MJ, Williamson DA, Hadway P, Doi SA, Gardiner RA, Paterson DL. Baseline prevalence of antimicrobial resistance and subsequent infection following prostate biopsy using empirical or altered prophylaxis: A bias-adjusted meta-analysis. *Int J Antimicrob Agents.* 2014;43(4):301–9. <https://doi.org/10.1016/j.ijantimicag.2014.01.008>
163. Nam RK, Saskin R, Lee Y, Liu Y, Law C, Klotz LH, et al. Increasing hospital admission rates for urological complications after transrectal ultrasound guided prostate biopsy. *J Urol.* 2013;189(1 Suppl):S12–7; discussion S7–8. <https://doi.org/10.1016/j.juro.2012.11.015>
164. Wagenlehner F, Stower-Hoffmann J, Schneider-Brachert W, Naber KG, Lehn N. Influence of a prophylactic single dose of ciprofloxacin on the level of resistance of *Escherichia coli* to fluoroquinolones in urology. *Int J Antimicrob Agents.* 2000;15(3):207–11. [https://doi.org/10.1016/S0924-8579\(00\)00182-5](https://doi.org/10.1016/S0924-8579(00)00182-5)
165. Alidjanov JF, Cai T, Bartoletti R, Bonkat G, Bruyere F, Koves B, et al. The negative aftermath of prostate biopsy: prophylaxis, complications and antimicrobial stewardship: results of the global prevalence study of infections in urology 2010–2019. *World J Urol.* 2021;39(9):3423–32. <https://doi.org/10.1007/s00345-021-03614-8>
166. Anastasiadis E, van der Meulen J, Emberton M. Hospital admissions after transrectal ultrasound-guided biopsy of the prostate in men diagnosed with prostate cancer: a database analysis in England. *Int J Urol.* 2015;22(2):181–6. <https://doi.org/10.1111/iju.12634>

167. Jiang P, Liss MA, Szabo RJ. Targeted Antimicrobial Prophylaxis Does Not Always Prevent Sepsis after Transrectal Prostate Biopsy. *J Urol*. 2018;200(2):361–8. <https://doi.org/10.1016/j.juro.2018.03.078>
168. Newman TH, Stroman L, Hadjipavlou M, Haque A, Rusere J, Chan K, et al. EXIT from TRAnsrectal prostate biopsies (TREXIT): sepsis rates of transrectal biopsy with rectal swab culture guided antimicrobials versus freehand transperineal biopsy. *Prostate Cancer Prostatic Dis*. 2021. <https://doi.org/10.1038/s41391-021-00438-w>
169. Bonkat G, Pilatz A, Wagenlehner F. Time to Adapt Our Practice? The European Commission Has Restricted the Use of Fluoroquinolones since March 2019. *Eur Urol*. 2019;76(3):273–5. <https://doi.org/10.1016/j.eururo.2019.06.011>
170. Baggio D, Ananda-Rajah MR. Fluoroquinolone antibiotics and adverse events. *Aust Prescr*. 2021;44(5):161–4. <https://doi.org/10.18773/austprescr.2021.035>
171. Noreikaite J, Jones P, Fitzpatrick J, Amitharaj R, Pietropaolo A, Vasdev N, et al. Fosfomycin vs. quinolone-based antibiotic prophylaxis for transrectal ultrasound-guided biopsy of the prostate: a systematic review and meta-analysis. *Prostate Cancer Prostatic Dis*. 2018;21(2):153–60. <https://doi.org/10.1038/s41391-018-0032-2>
172. Roberts MJ, Scott S, Harris PN, Naber K, Wagenlehner FME, Doi SAR. Comparison of fosfomycin against fluoroquinolones for transrectal prostate biopsy prophylaxis: an individual patient-data meta-analysis. *World J Urol*. 2018;36(3):323–30. <https://doi.org/10.1007/s00345-017-2163-9>
173. Bjerklund Johansen TE, Kulchavenya E, Lentz GM, Livermore DM, Nickel JC, Zhanel G, et al. Fosfomycin Trometamol for the Prevention of Infectious Complications After Prostate Biopsy: A Consensus Statement by an International Multidisciplinary Group. *Eur Urol Focus*. 2021. <https://doi.org/10.1016/j.euf.2021.11.007>
174. Wenzel M, von Hardenberg J, Welte MN, Doryumu S, Hoeh B, Wittler C, et al. Monoprophylaxis With Cephalosporins for Transrectal Prostate Biopsy After the Fluoroquinolone-Era: A Multi-Institutional Comparison of Severe Infectious Complications. *Front Oncol*. 2021;11:684144. <https://doi.org/10.3389/fonc.2021.684144>
175. Hori S, Sengupta A, Joannides A, Balogun-Ojuri B, Tilley R, McLoughlin J. Changing antibiotic prophylaxis for transrectal ultrasound-guided prostate biopsies: are we putting our patients at risk? *BJU Int*. 2010;106(9):1298–302; discussion 302. <https://doi.org/10.1111/j.1464-410X.2010.09416.x>
176. Madden T, Doble A, Aliyu SH, Neal DE. Infective complications after transrectal ultrasound-guided prostate biopsy following a new protocol for antibiotic prophylaxis aimed at reducing hospital-acquired infections. *BJU Int*. 2011;108(10):1597–602. <https://doi.org/10.1111/j.1464-410X.2011.10160.x>
177. Bloomfield MG, Wilson AD, Studd RC, Blackmore TK. Highly effective prophylaxis with ertapenem for transrectal ultrasound-guided prostate biopsy: effects on overall antibiotic use and inpatient hospital exposure. *J Hosp Infect*. 2020;106(3):483–9. <https://doi.org/10.1016/j.jhin.2020.08.020>
178. Seitz M, Stief C, Waidelich R, Bader M, Tilki D. Transrectal ultrasound guided prostate biopsy in the era of increasing fluoroquinolone resistance: prophylaxis with single-dose ertapenem. *World J Urol*. 2017;35(11):1681–8. <https://doi.org/10.1007/s00345-017-2043-3>
179. Bloomfield MG, Page MJ, McLachlan AG, Studd RC, Blackmore TK. Routine Ertapenem Prophylaxis for Transrectal Ultrasound Guided Prostate Biopsy does Not Select for Carbapenem Resistant Organisms: A Prospective Cohort Study. *J Urol*. 2017;198(2):362–8. <https://doi.org/10.1016/j.juro.2017.03.077>
180. Samarinas M, Dimitropoulos K, Zachos I, Gravas S, Karatzas A, Tzortzis V. A single dose of meropenem is superior to ciprofloxacin in preventing infections after transrectal ultrasound-guided prostate biopsies in the era of quinolone resistance. *World J Urol*. 2016;34(11):1555–9. <https://doi.org/10.1007/s00345-016-1800-z>
181. Liss MA, Ehdaie B, Loeb S, Meng MV, Raman JD, Spears V, et al. An Update of the American Urological Association White Paper on the Prevention and Treatment of the More Common Complications Related to Prostate Biopsy. *J Urol*. 2017;198(2):329–34. <https://doi.org/10.1016/j.juro.2017.01.103>
182. Bennett HY, Roberts MJ, Doi SA, Gardiner RA. The global burden of major infectious complications following prostate biopsy. *Epidemiol Infect*. 2016;144(8):1784–91. <https://doi.org/10.1017/S0950268815002885>
183. Eldred-Evans D, Kasivisvanathan V, Khan F, Hemelrijck MV, Polson A, Acher P, et al. The Use of Transperineal Sector Biopsy as A First-Line Biopsy Strategy: A Multi-Institutional Analysis of Clinical Outcomes and Complications. *Urol J*. 2016;13(5):2849–55.

184. Huang H, Wang W, Lin T, Zhang Q, Zhao X, Lian H, et al. Comparison of the complications of traditional 12 cores transrectal prostate biopsy with image fusion-guided transperineal prostate biopsy. *BMC Urol.* 2016;16(1):68. <https://doi.org/10.1186/s12894-016-0185-z>
185. Castellani D, Pirola GM, Law YXT, Gubbiotti M, Giuliani C, Scarcella S, et al. Infection Rate after Transperineal Prostate Biopsy with and without Prophylactic Antibiotics: Results from a Systematic Review and Meta-Analysis of Comparative Studies. *J Urol.* 2022;207(1):25–34. <https://doi.org/10.1097/JU.0000000000002251>
186. Ding XF, Luan Y, Lu SM, Zhou GC, Huang TB, Zhu LY, et al. Risk factors for infection complications after transrectal ultrasound-guided transperineal prostate biopsy. *World J Urol.* 2021;39(7):2463–7. <https://doi.org/10.1007/s00345-020-03454-y>
187. Kohl T, Sigle A, Kuru T, Salem J, Rolfs H, Kowalke T, et al. Comprehensive analysis of complications after transperineal prostate biopsy without antibiotic prophylaxis: results of a multi-center trial with 30 days' follow-up. *Prostate Cancer Prostatic Dis.* 2021. <https://doi.org/10.1038/s41391-021-00423-3>
188. Tohi Y, Fujiwara K, Harada S, Matsuda I, Ito A, Yamasaki M, et al. Positive Culture Prior to Transperineal Prostate Biopsy Was Not Associated with Post-Biopsy Febrile Urinary Tract Infection Development. *Res Rep Urol.* 2021;13:691–8. <https://doi.org/10.2147/RRU.S333724>
189. Berry B, Parry MG, Sujenthiran A, Nossiter J, Cowling TE, Aggarwal A, et al. Comparison of complications after transrectal and transperineal prostate biopsy: a national population-based study. *BJU Int.* 2020;126(1):97–103. <https://doi.org/10.1111/bju.15039>
190. Carmignani L, Picozzi S, Bozzini G, Negri E, Ricci C, Gaeta M, et al. Transrectal ultrasound-guided prostate biopsies in patients taking aspirin for cardiovascular disease: A meta-analysis. *Transfus Apher Sci.* 2011;45(3):275–80. <https://doi.org/10.1016/j.transci.2011.10.008>
191. Wang J, Zhang C, Tan G, Chen W, Yang B, Tan D. Risk of bleeding complications after preoperative antiplatelet withdrawal versus continuing antiplatelet drugs during transurethral resection of the prostate and prostate puncture biopsy: a systematic review and meta-analysis. *Urol Int.* 2012;89(4):433–8. <https://doi.org/10.1159/000343733>
192. Culkun DJ, Exaire EJ, Green D, Soloway MS, Gross AJ, Desai MR, et al. Anticoagulation and antiplatelet therapy in urological practice: ICUD/AUA review paper. *J Urol.* 2014;192(4):1026–34. <https://doi.org/10.1016/j.juro.2014.04.103>
193. Chowdhury R, Abbas A, Idriz S, Hoy A, Rutherford EE, Smart JM. Should warfarin or aspirin be stopped prior to prostate biopsy? An analysis of bleeding complications related to increasing sample number regimes. *Clin Radiol.* 2012;67(12):e64–70. <https://doi.org/10.1016/j.crad.2012.08.005>
194. Ihezue CU, Smart J, Dewbury KC, Mehta R, Burgess L. Biopsy of the prostate guided by transrectal ultrasound: relation between warfarin use and incidence of bleeding complications. *Clin Radiol.* 2005;60(4):459–63; discussion 7–8. <https://doi.org/10.1016/j.crad.2004.10.014>
195. Raheem OA, Casey RG, Galvin DJ, Manecksha RP, Varadaraj H, McDermott T, et al. Discontinuation of anticoagulant or antiplatelet therapy for transrectal ultrasound-guided prostate biopsies: a single-center experience. *Korean J Urol.* 2012;53(4):234–9. <https://doi.org/10.4111/kju.2012.53.4.234>
196. Brewster S, Turkeri L, Brausi M, Ravery V, Djavan B. 5A prospective survey of current prostate biopsy practices among oncological urologists. *Can J Urol.* 2010;17(2):5071–6.
197. Coscarella M, Motte S, Dalati MF, Oliveira EST, Entezari K, Roumeguere T. New oral anti-coagulation drugs and prostate biopsy: a call for guidelines. *Ther Adv Urol.* 2018;10(12):437–43. <https://doi.org/10.1177/1756287218811037>
198. Saito K, Washino S, Nakamura Y, Konishi T, Ohshima M, Arai Y, et al. Transperineal ultrasound-guided prostate biopsy is safe even when patients are on combination antiplatelet and/or anticoagulation therapy. *BMC Urol.* 2017;17(1):53. <https://doi.org/10.1186/s12894-017-0245-z>
199. Fainberg J, Gaffney CD, Pierce H, Aboukshaba A, Chughtai B, Christos P, et al. Erectile Dysfunction is a Transient Complication of Prostate Biopsy: A Systematic Review and Meta-Analysis. *J Urol.* 2021;205(3):664–70. <https://doi.org/10.1097/JU.0000000000001398>
200. Mehta A, Kim WC, Aswad KG, Brunckhorst O, Ahmed HU, Ahmed K. Erectile Function Post Prostate Biopsy: A Systematic Review and Meta-analysis. *Urology.* 2021;155:1–8. <https://doi.org/10.1016/j.urology.2021.01.035>

201. Volanis D, Neal DE, Warren AY, Gnanapragasam VJ. Incidence of needle-tract seeding following prostate biopsy for suspected cancer: a review of the literature. *BJU Int.* 2015;115(5):698–704. <https://doi.org/10.1111/bju.12849>
202. Pinsky PF, Parnes HL, Andriole G. Mortality and complications after prostate biopsy in the Prostate, Lung, Colorectal and Ovarian Cancer Screening (PLCO) trial. *BJU Int.* 2014;113(2):254–9. <https://doi.org/10.1111/bju.12368>
203. Carlsson SV, Holmberg E, Moss SM, Roobol MJ, Schroder FH, Tammela TL, et al. No excess mortality after prostate biopsy: results from the European Randomized Study of Screening for Prostate Cancer. *BJU Int.* 2011;107(12):1912–7. <https://doi.org/10.1111/j.1464-410X.2010.09712.x>